



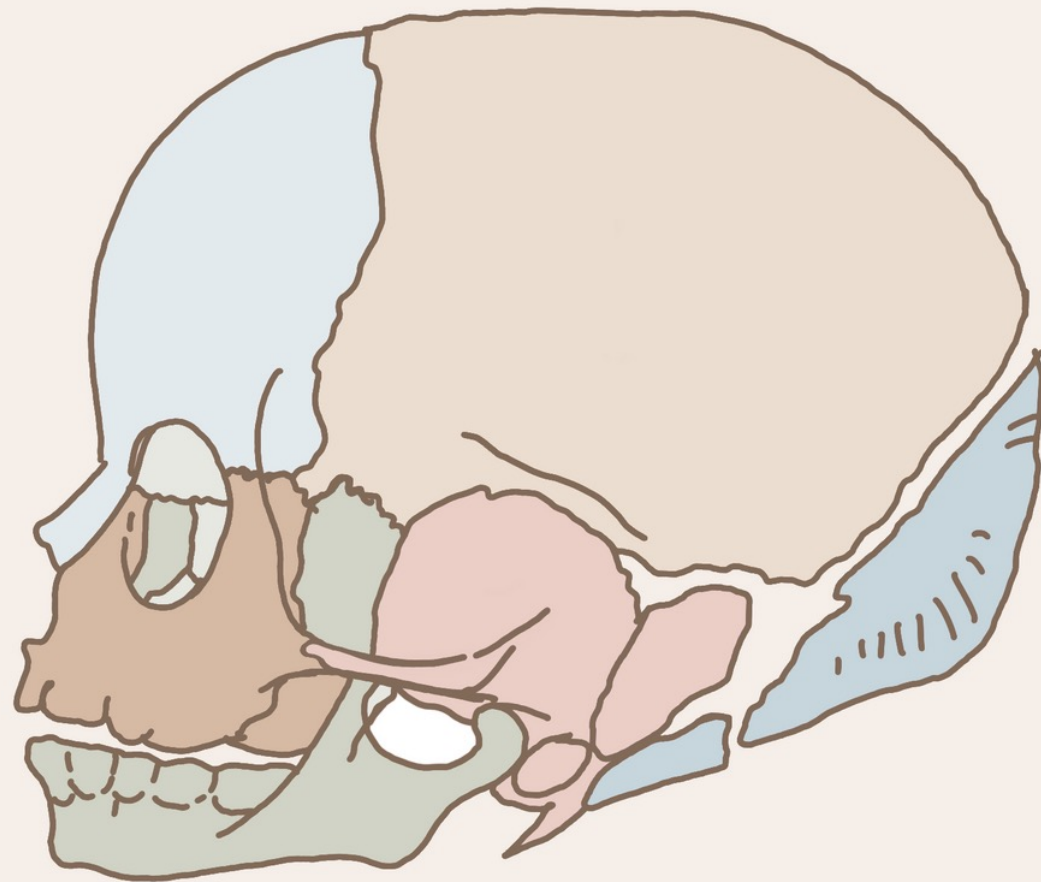
happybabycoach
Minder twijfels meer Momfidencel!

Anja Caers

Osteopaat D.O.
Bezieler van Happybabycoach

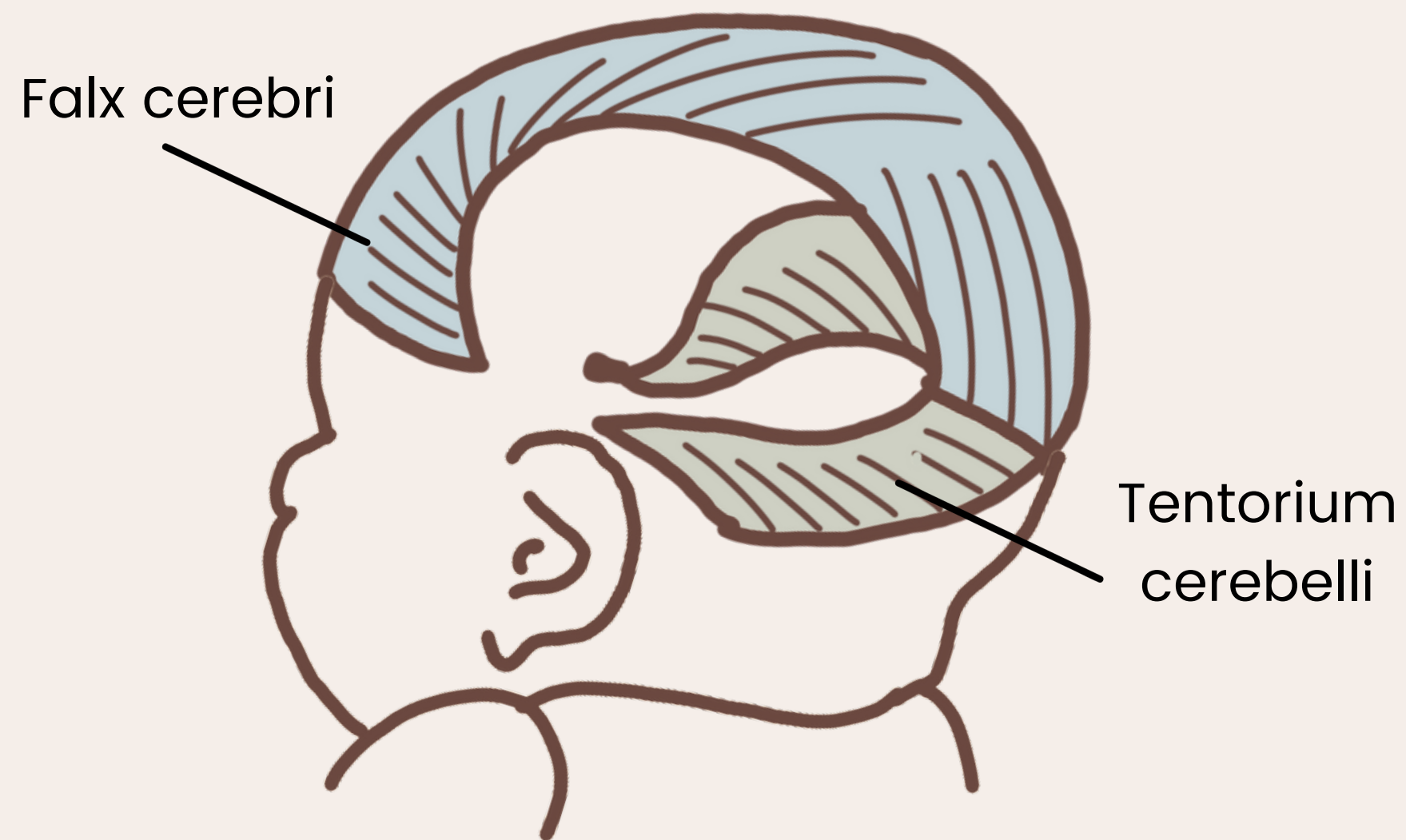
Borstvoeding na geboortetrauma

De schedel van een pasgeborene



- boteilandjes, ingebed in membraneus weefsel
- Zacht, flexibel, vervormbaar
- moulding tijdens geboorte

Schedelmembranen



- **Dura mater**

- falx cerebri
- falx cerebelli
- tentorium cerebelli
- anterior durale gordel



Emma

6

weken

Emma

Hulpvraag

- Voedingen zijn een 'gevecht, veel onrust, huilen en onderbrekingen
- mama: borstontstekingen, tepelkloven (beide borsten)
- Na de voeding: huilen, lang rechthouden, lang naboeren
- Gewicht: komt traag bij, zakt lichtjes op de P-curve

Kinderarts

- Tongriem geknipt op 3 weken
- Op 4 weken: gaviscon + voeding kolven en indikken JBPM

Vroedvrouw

- kleine aanhap en fel klemmen, weinig zuigkracht -> stuurde door voor osteopathie.

Zwangerschap

- 1e kindje, fijne, vlotte zwangerschap

Geboorte

- a term, vliezen spontaan gebroken
- na 14 uur arbeid: 4 cm ontsluiting: oxytocine-infuus -> 6u later volledige ontsluiting
- occiput posterior ligging + navelstreng rond nekje
- 1,5 u geperst

Pitmekaart

Dag 1

7u	8u	9u	10u	11u	12u	13u	14u	15u	16u	17u	18u	19u	20u	21u	22u	23u	24u	1u	2u	3u	4u	5u	6u	

Dag 2


7u	8u	9u	10u	11u	12u	13u	14u	15u	16u	17u	18u	19u	20u	21u	22u	23u	24u	1u	2u	3u	4u	5u	6u	

Dag 3


7u	8u	9u	10u	11u	12u	13u	14u	15u	16u	17u	18u	19u	20u	21u	22u	23u	24u	1u	2u	3u	4u	5u	6u	



Slapen



Huilerig
(troostbaar)



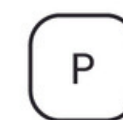Huilen
(ontroostbaar)



Voeding



Ontlasting



Plassen

	8u	9u	10u	11u	12u	13u	14u	15u	16u	17u	18u	19u	20u	21u	22u	23u	24u	1u	2u	3u	4u	5u	6u	7u	
Dag1		V O		V			V O			V V	V			V V V					V					V O	

recht op
houden

op mijn borst
geslapen

	8u	9u	10u	11u	12u	13u	14u	15u	16u	17u	18u	19u	20u	21u	22u	23u	24u	1u	2u	3u	4u	5u	6u	7u	
Dag2	V		V O		V		V O			V	O	V	O	V V				V			V			V	

draagdoek

	8u	9u	10u	11u	12u	13u	14u	15u	16u	17u	18u	19u	20u	21u	22u	23u	24u	1u	2u	3u	4u	5u	6u	7u	
Dag3		V O		V				V		V			V	V V			V						V		



Slapen



Huilerig
(troostbaar)



Huilen
(ontroostbaar)

V

Voeding

O

Ontlasting

P

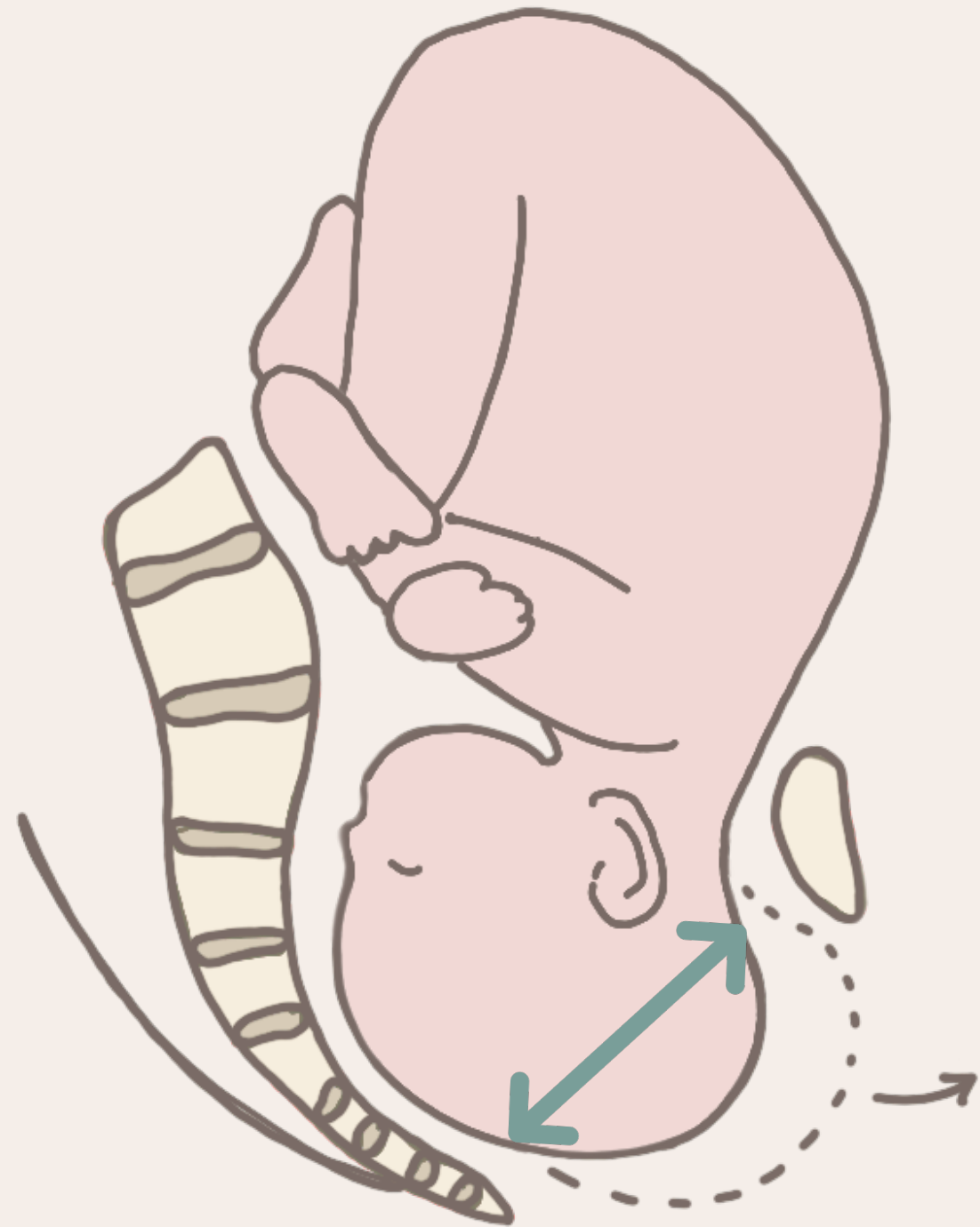
Plassen



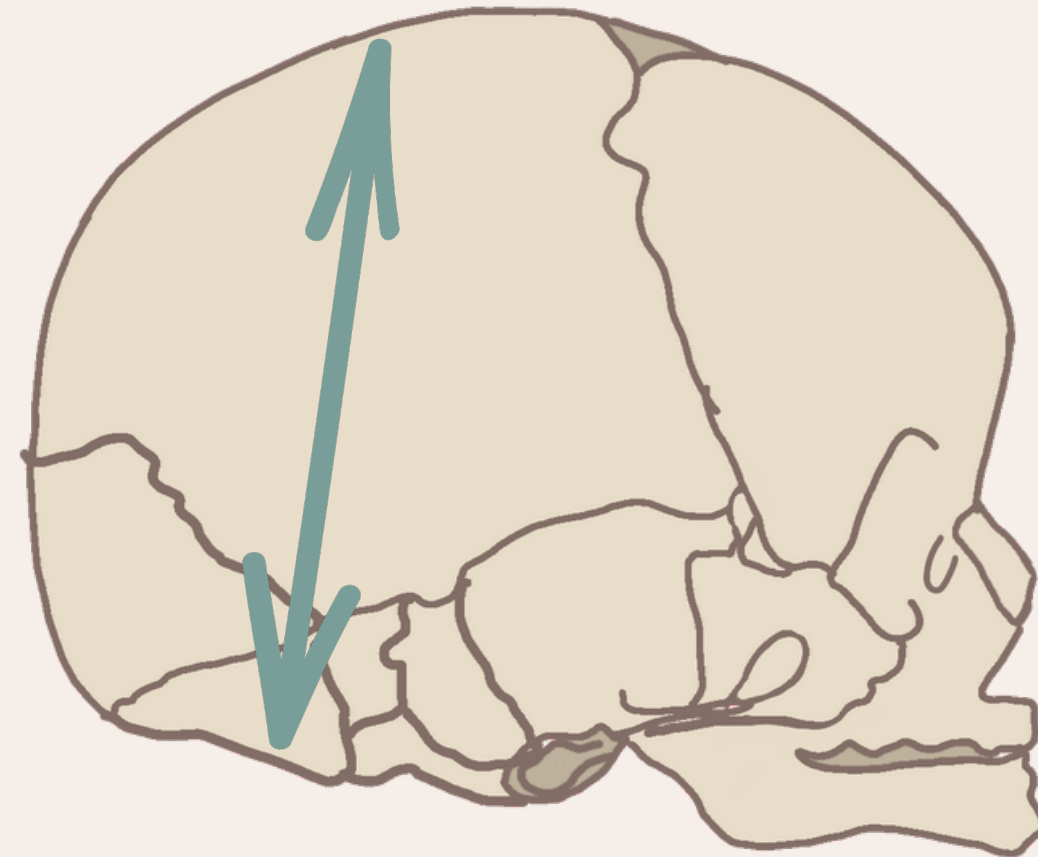
Emma

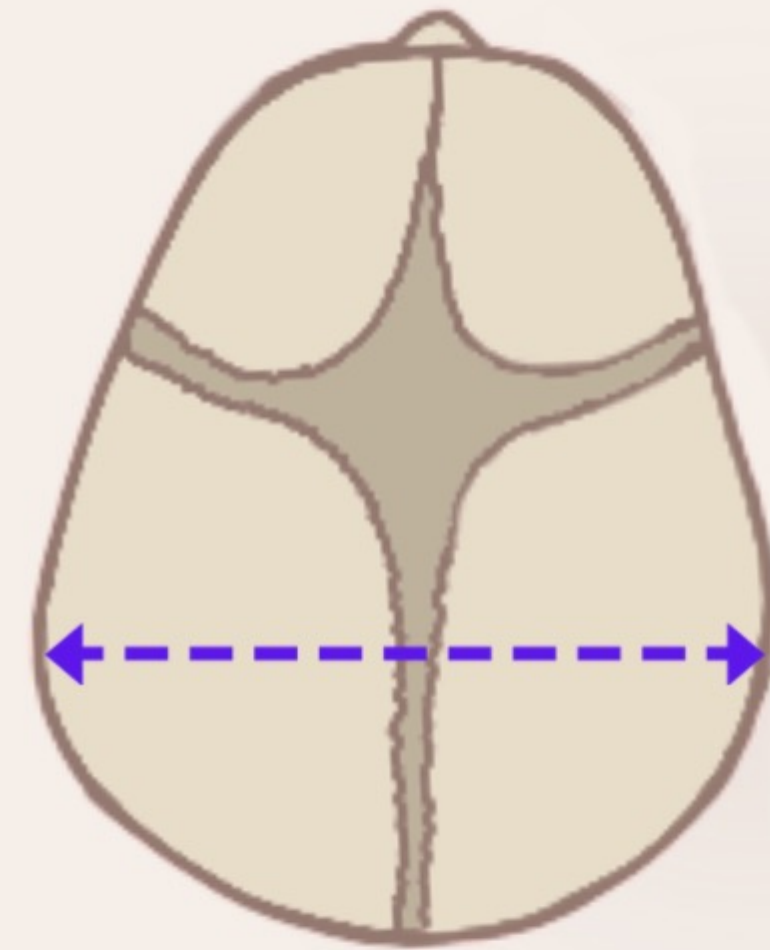
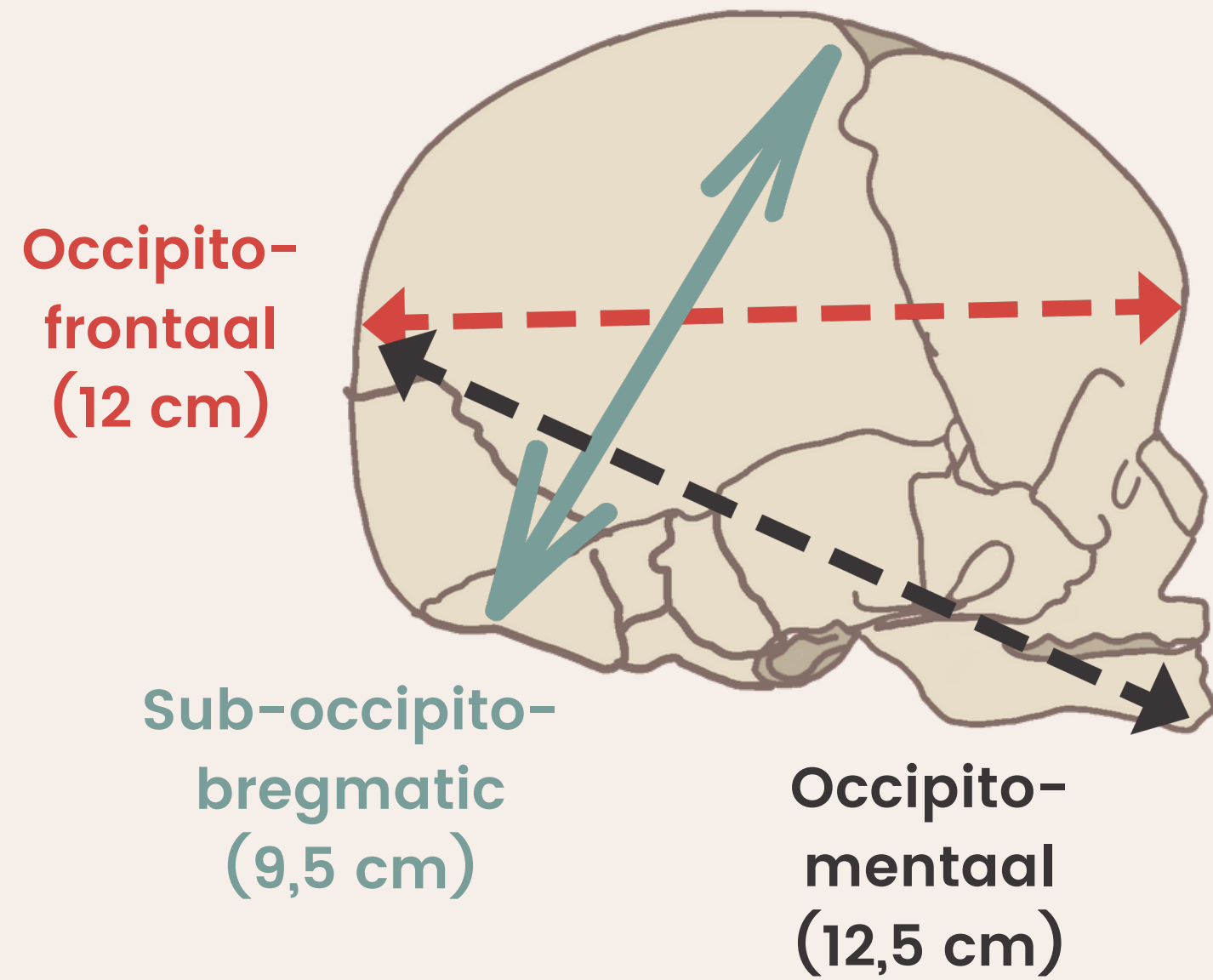
Osteopatisch

- occipitale condylen bilateraal posterior
- hyoid (tongbeentje) in superior positie
- maag in superior positie

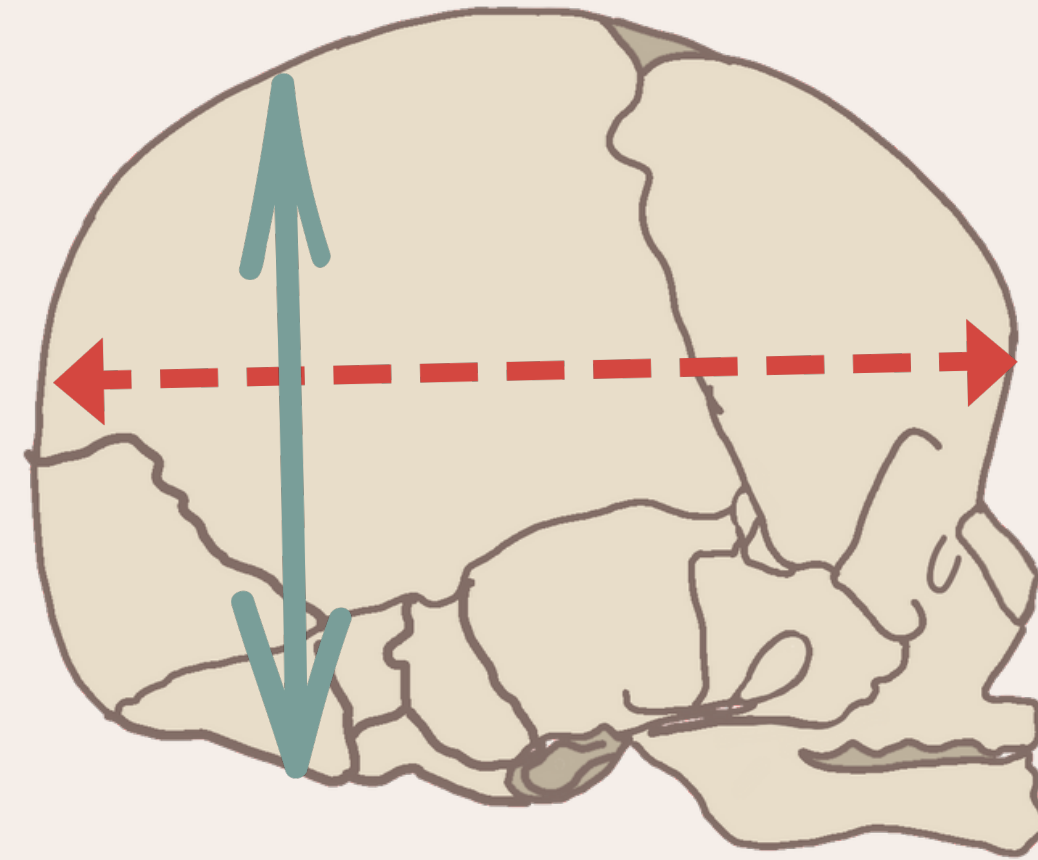
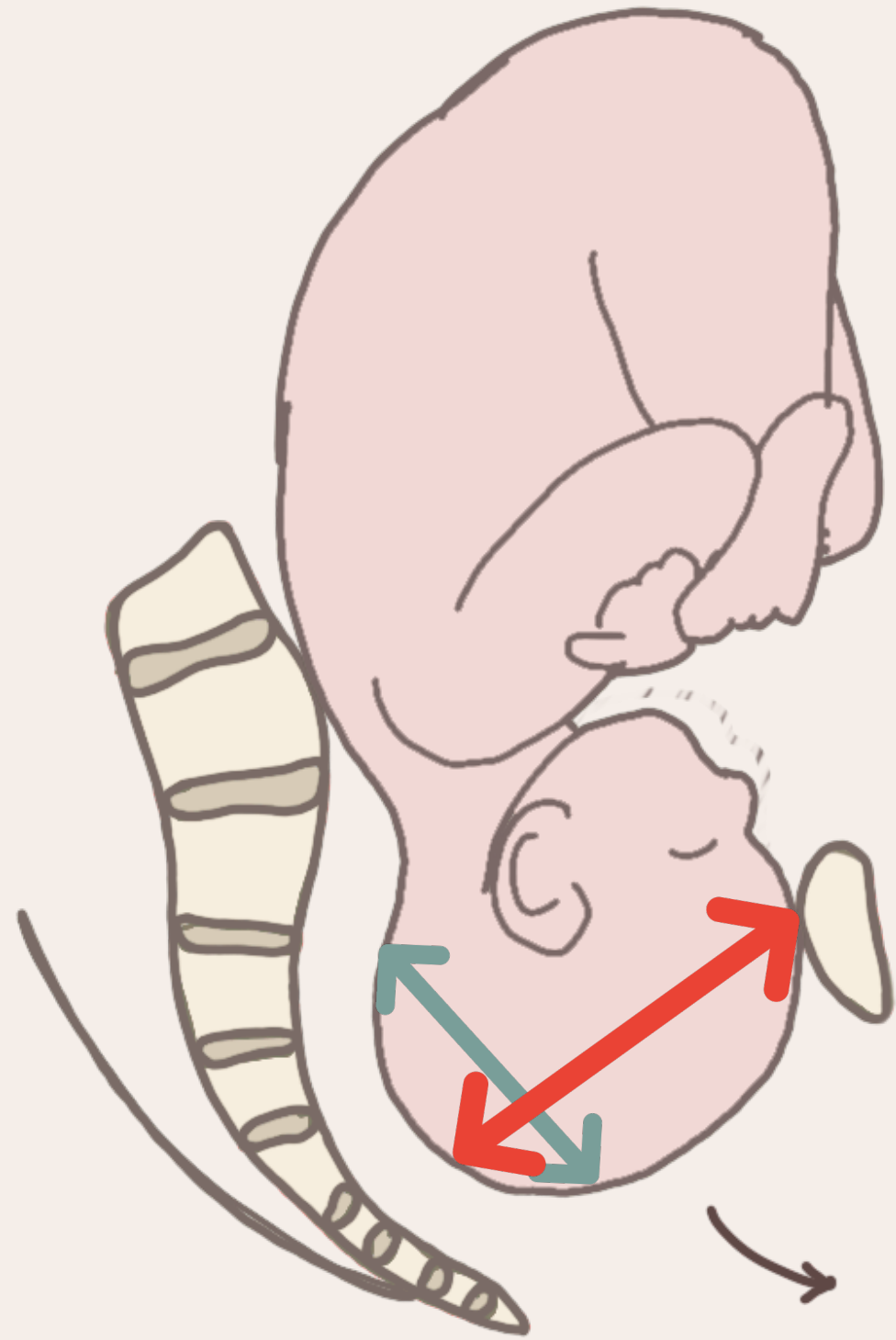


**Occiput Anterior
Positie**

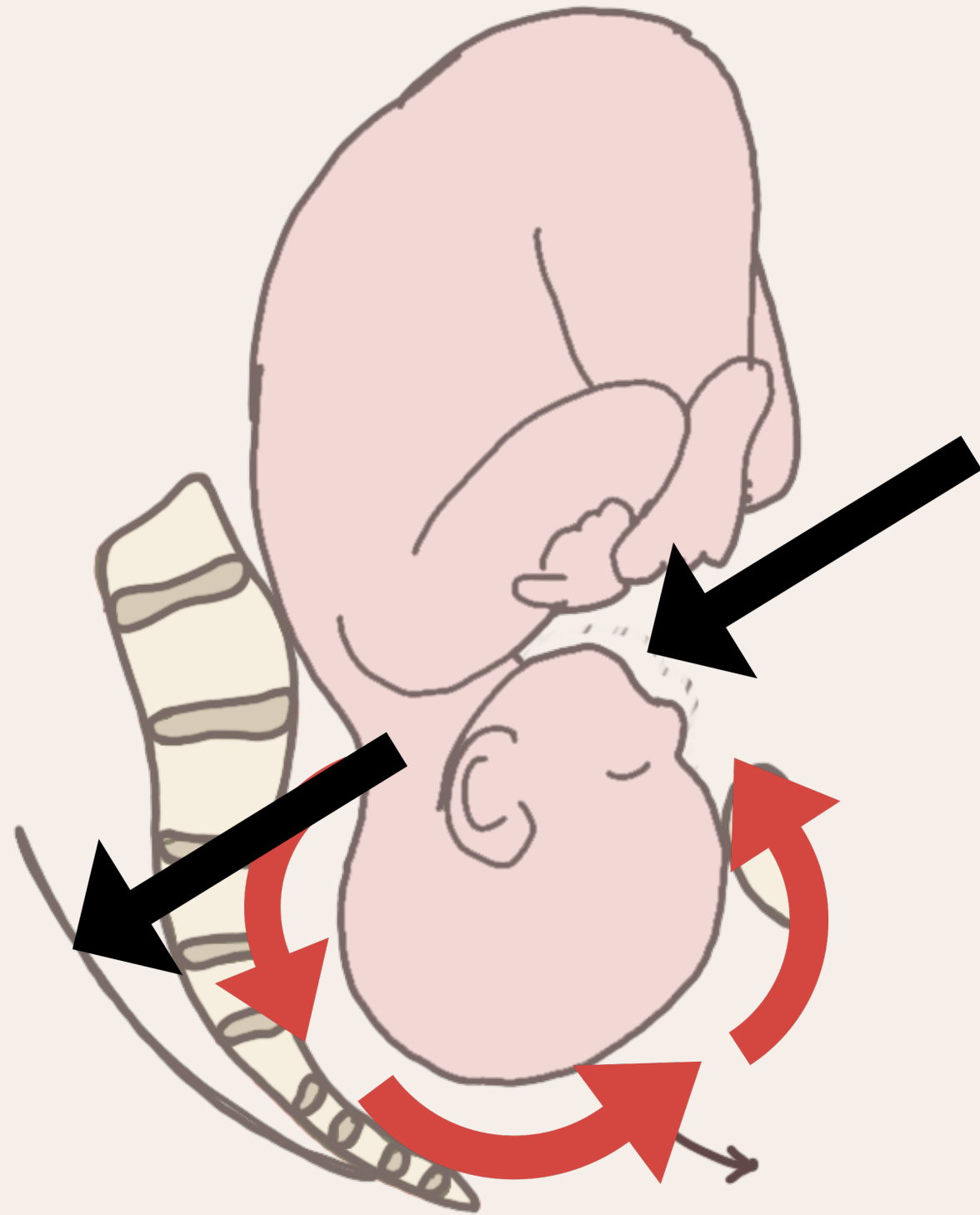


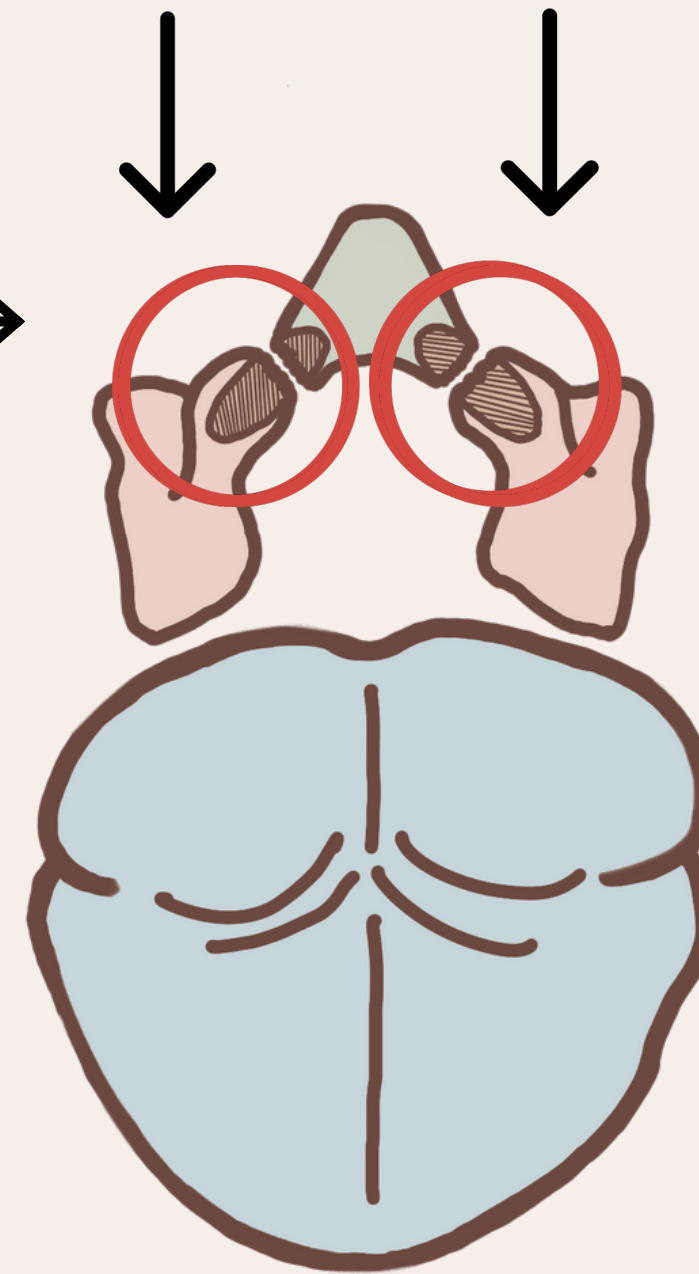
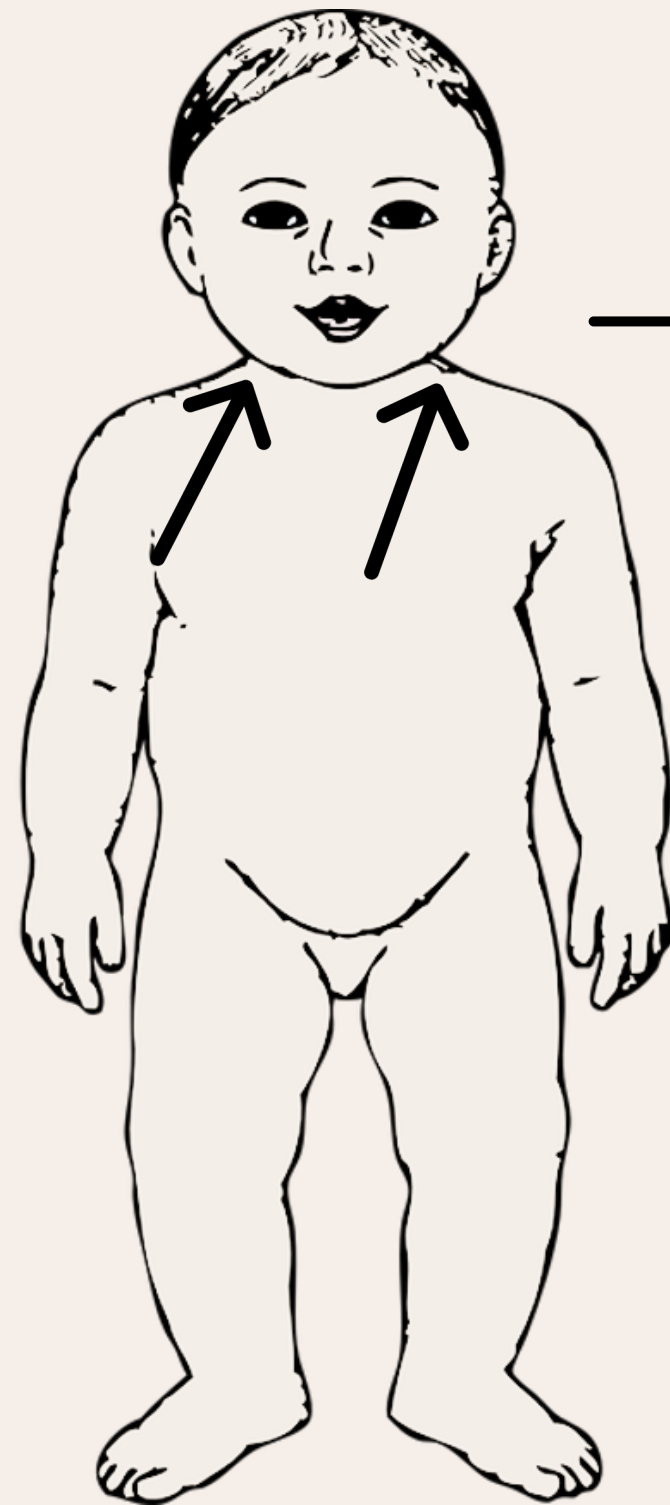


Bi-parietaal (9 cm)



Occiput Posterior Positie

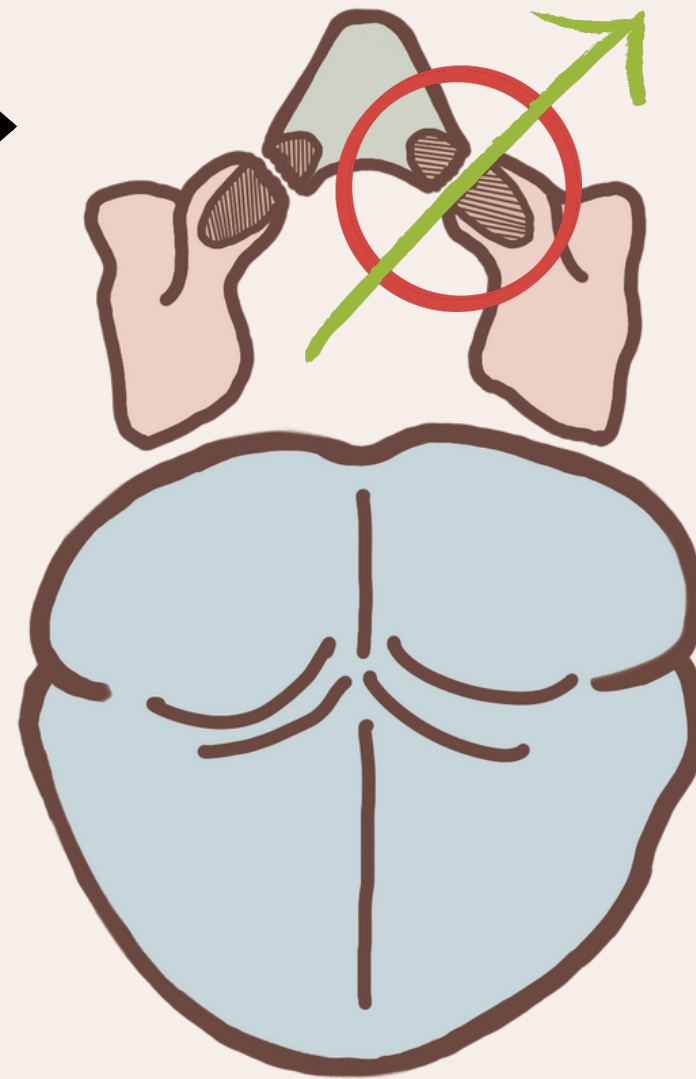
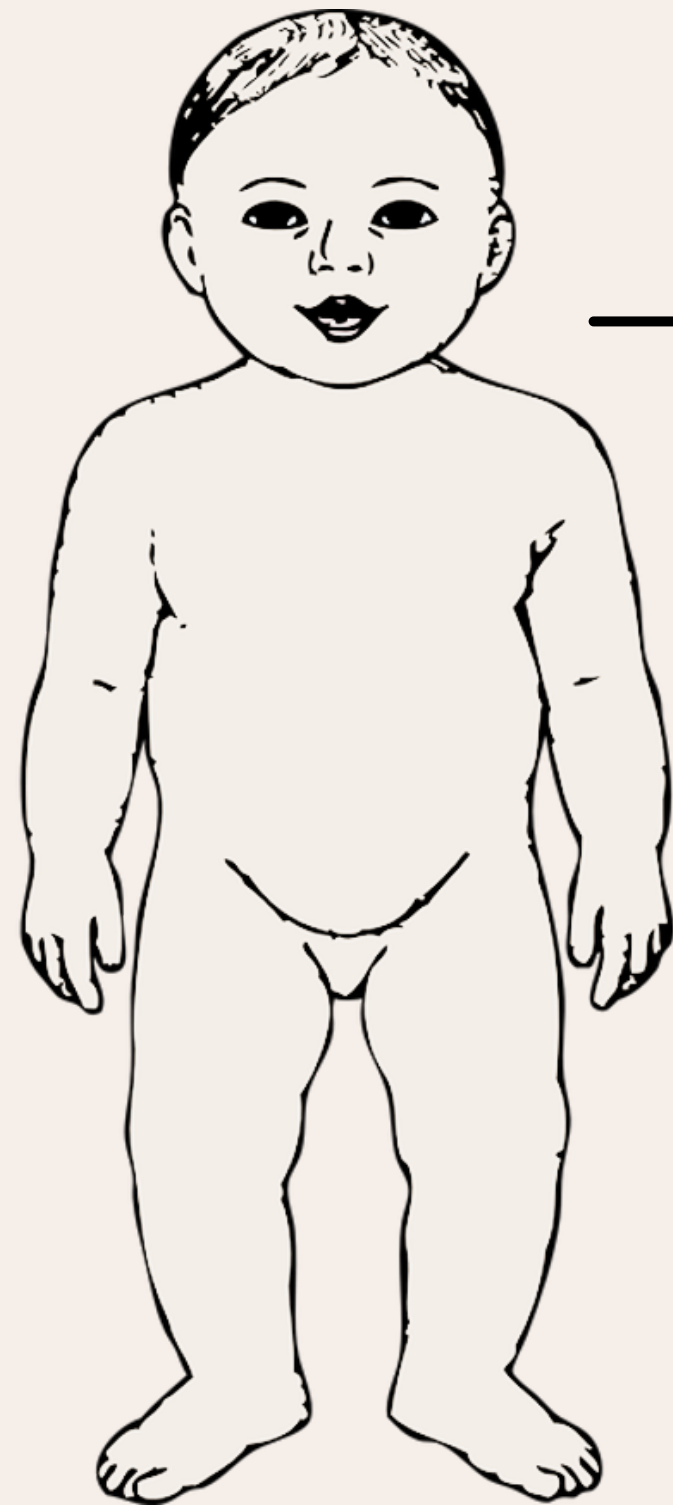




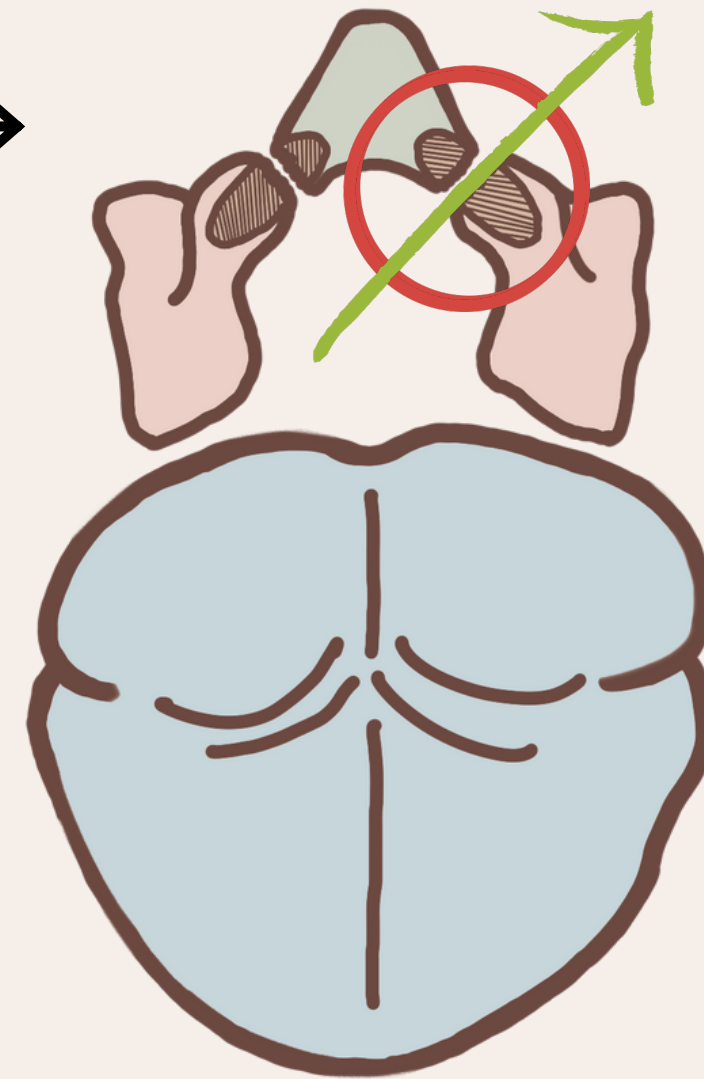
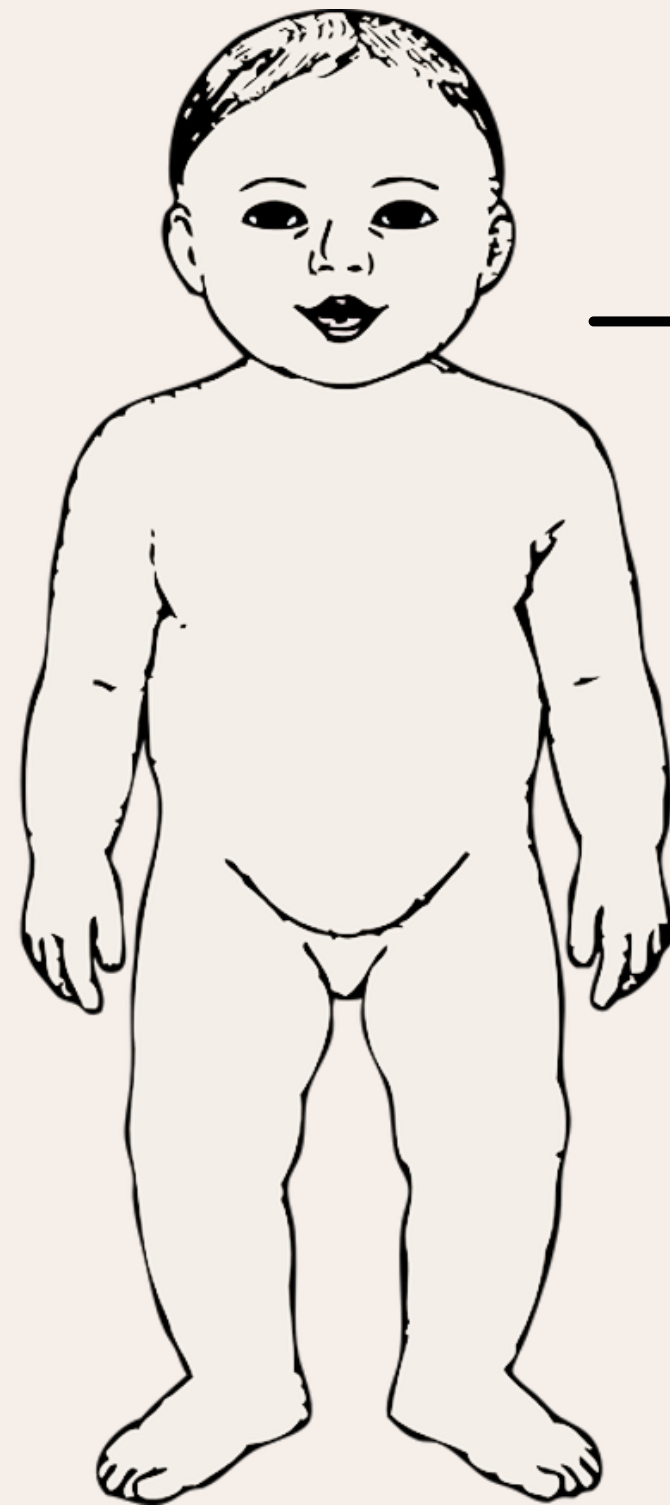
C0 t.o.v. C1
Occiput in
posterior
positie



*Kan hoofdje niet
vlot achterwaarts
kantelen.*



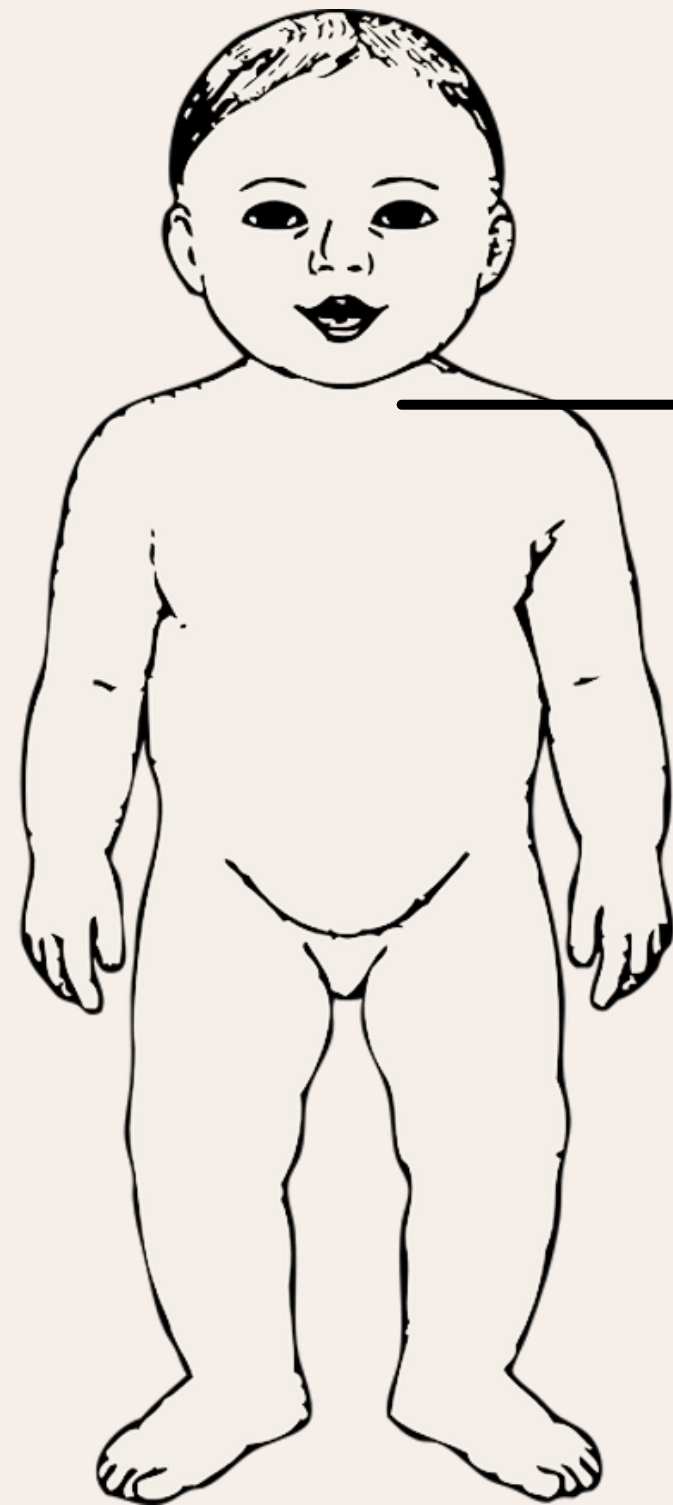
N.
Hypoglossus
(in canalis
Hyppoglossus)



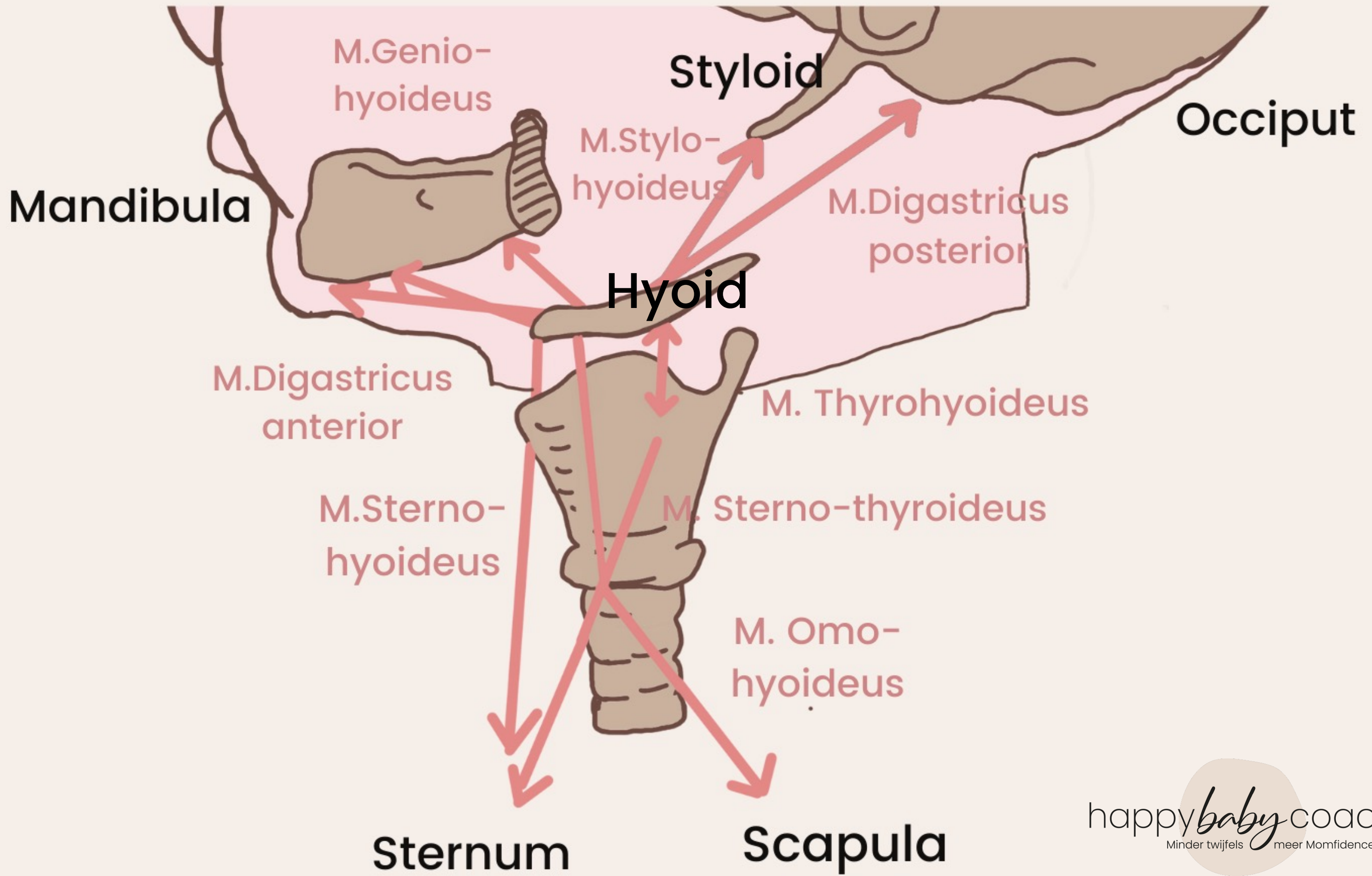
N.
Hypoglossus
(in canalis
Hypoglossus)

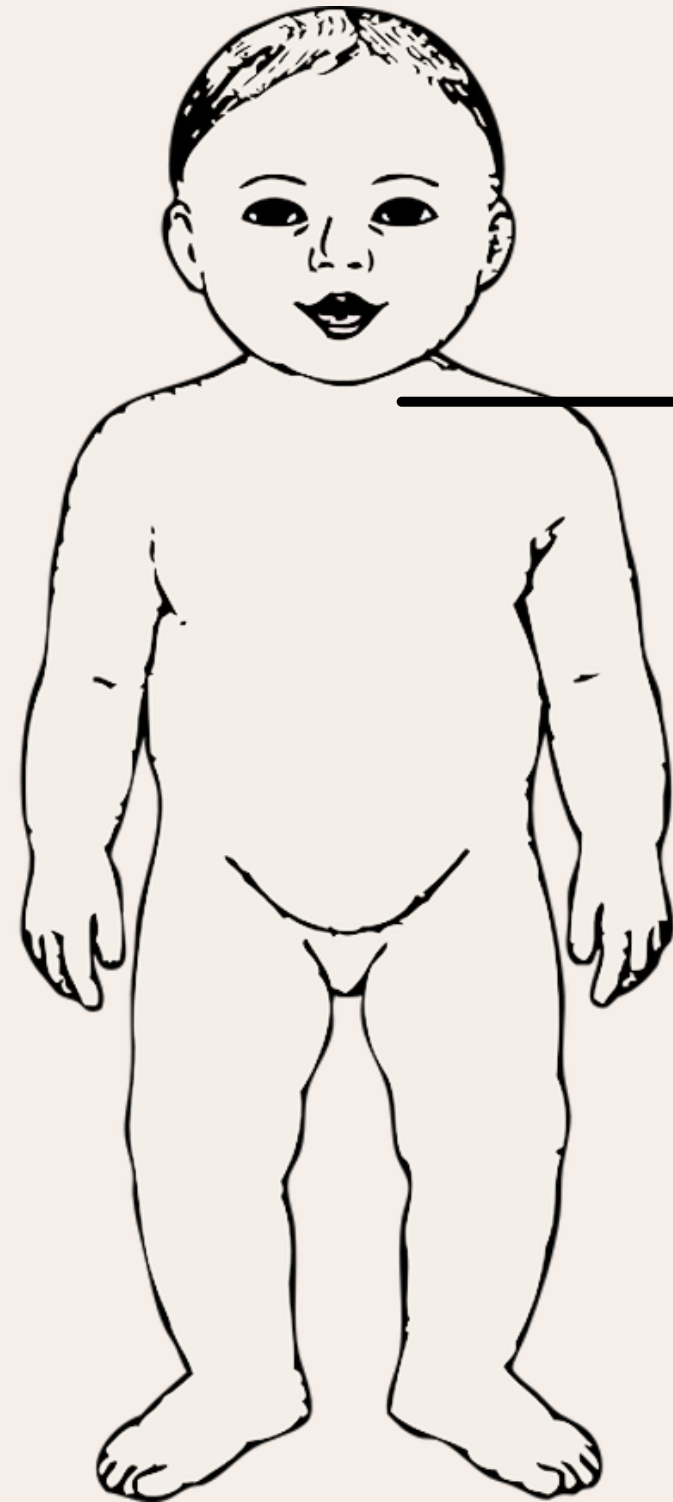
*verminderde
tongfunctie*





Hyoid
in superior
positie





Hyoid in superior positie

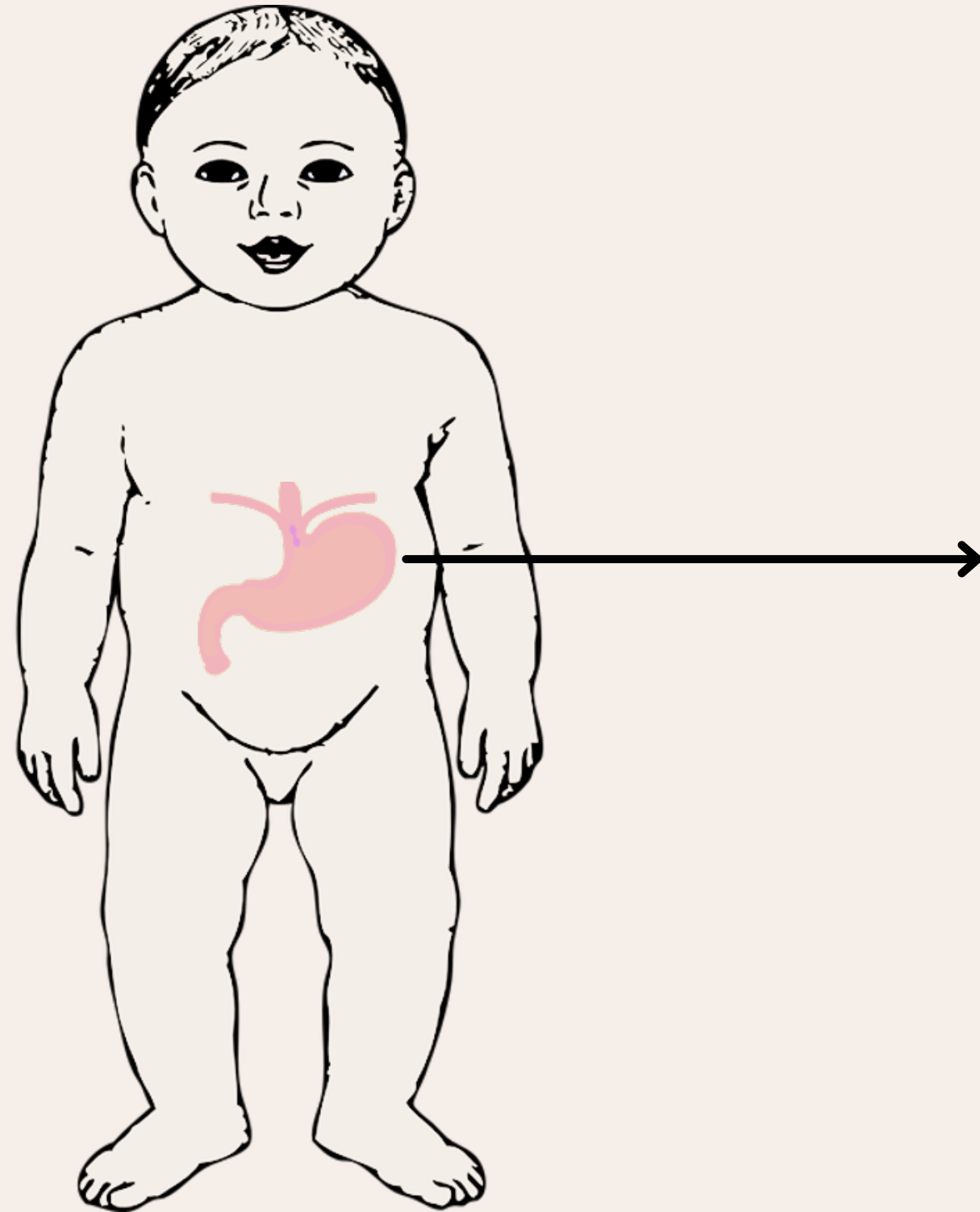
1) tongfunctie

belemmerd

2) verstoorde werking

slakdarm



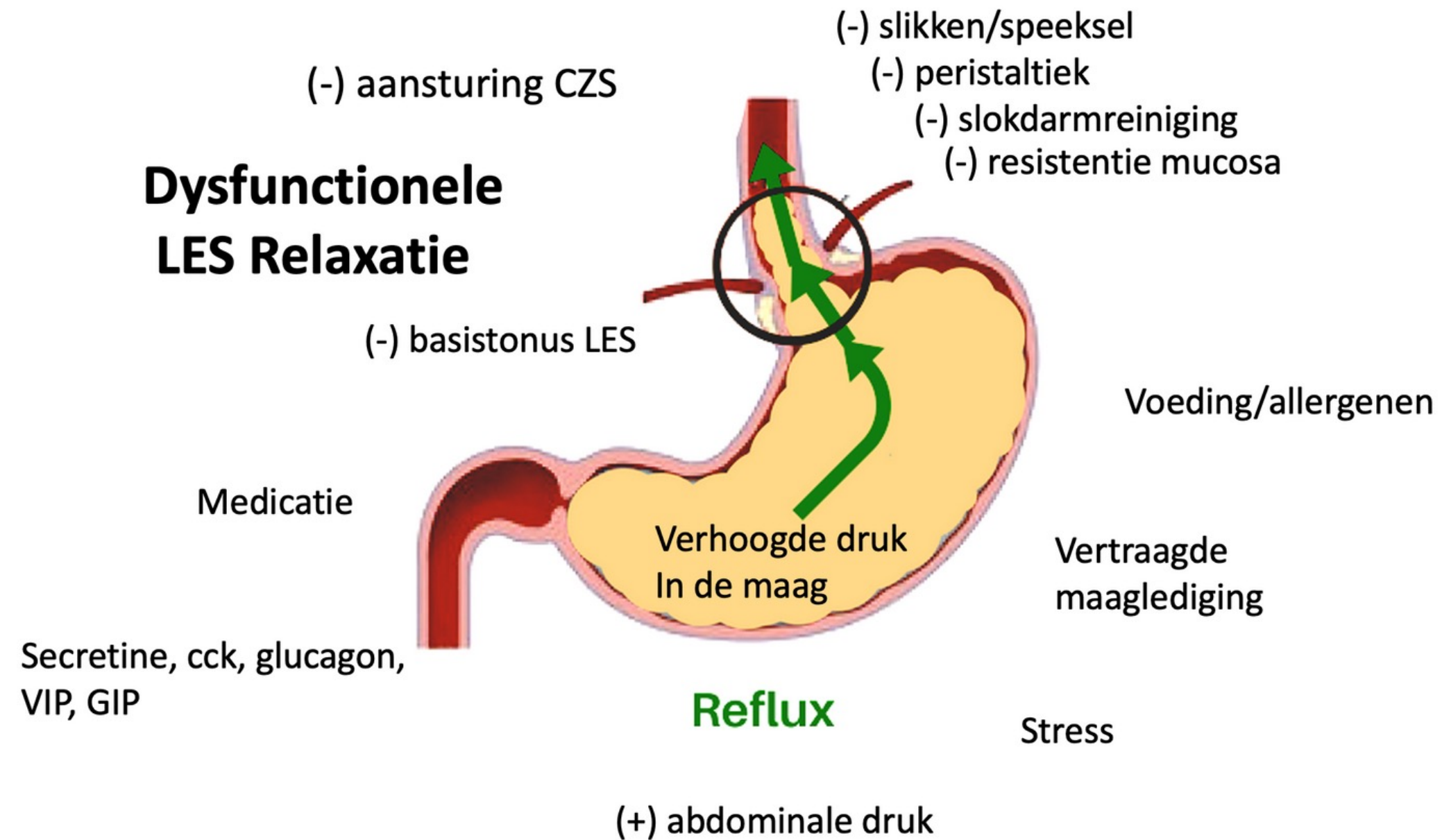


**Diafragma/maag
in superior
positie**



*Minder goede afsluiting onderste
oesophagale sfincter*

Pathofysiologie GERD



Emma

Behandeling

- occipitale condylen
- hyoid (tongbeentje)
- maag

Advisering

- Frequentie voedingen: oké
- Borst goed leegdrinken

Zoeken, aanhappen,
zuigen, slikken

Hoofdje draait
& kantelt
achterwaarts



*Zoeken &
aanhappen*



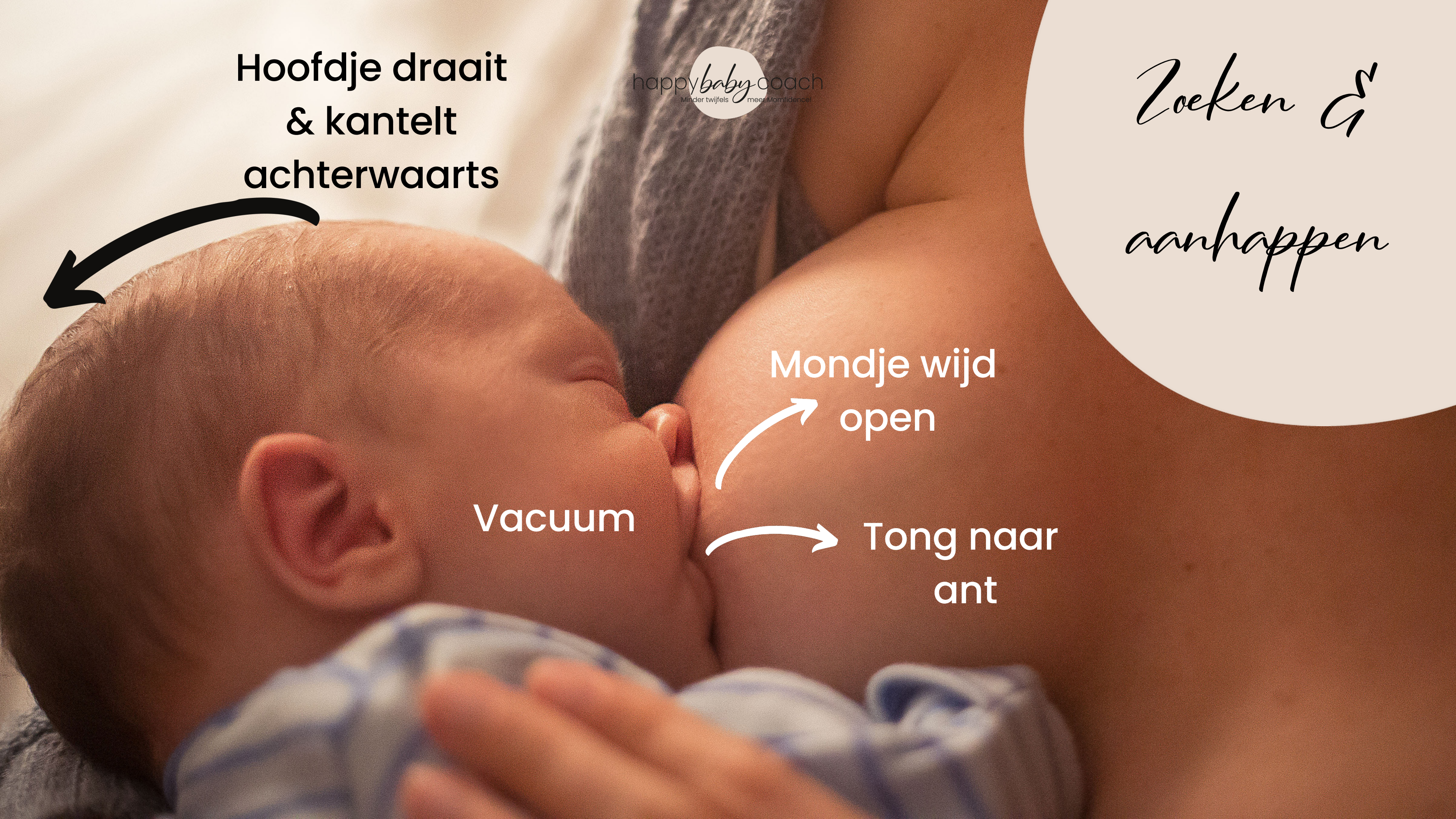
Mondje wijd
open

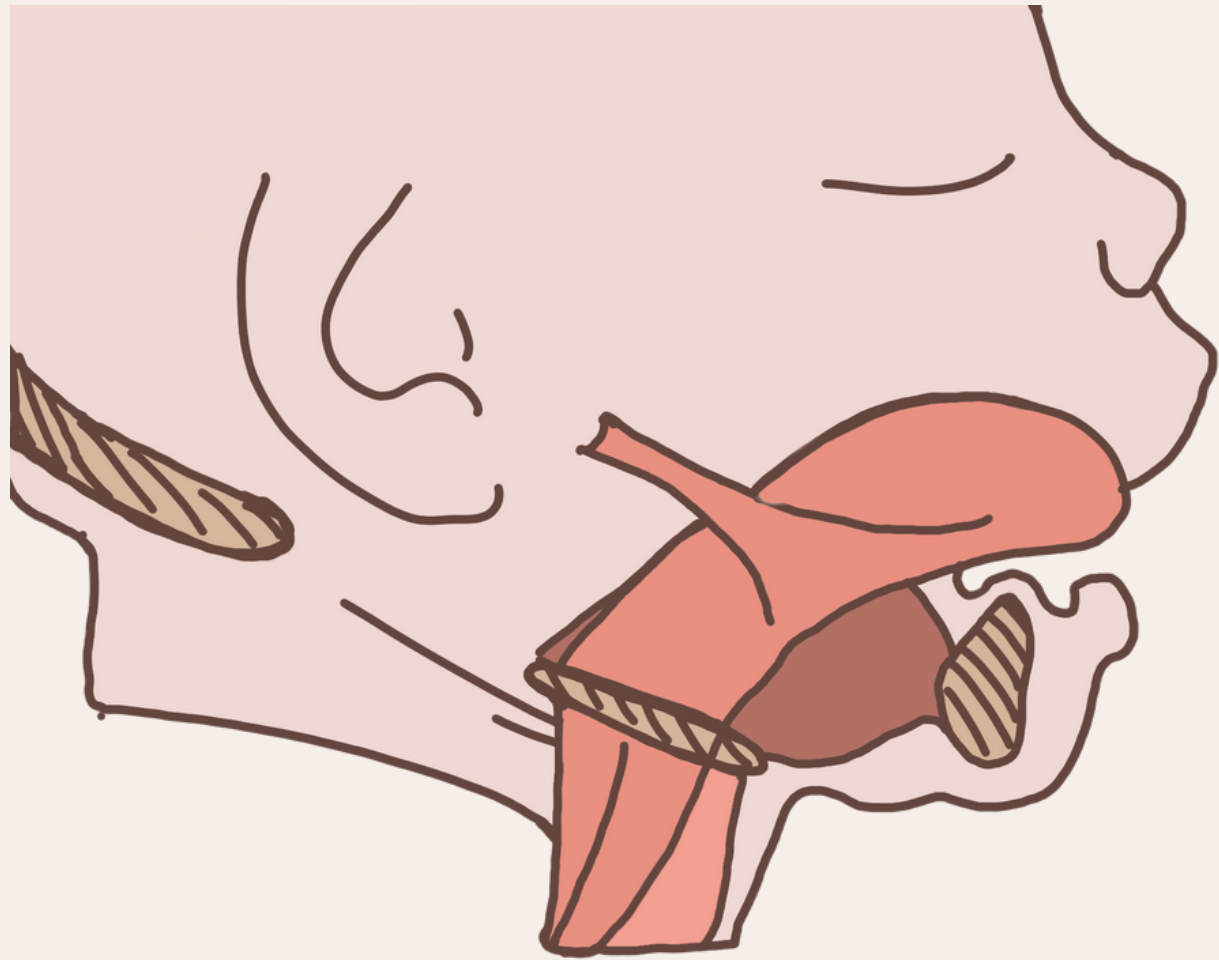


Vacuüm



Tong naar
ant



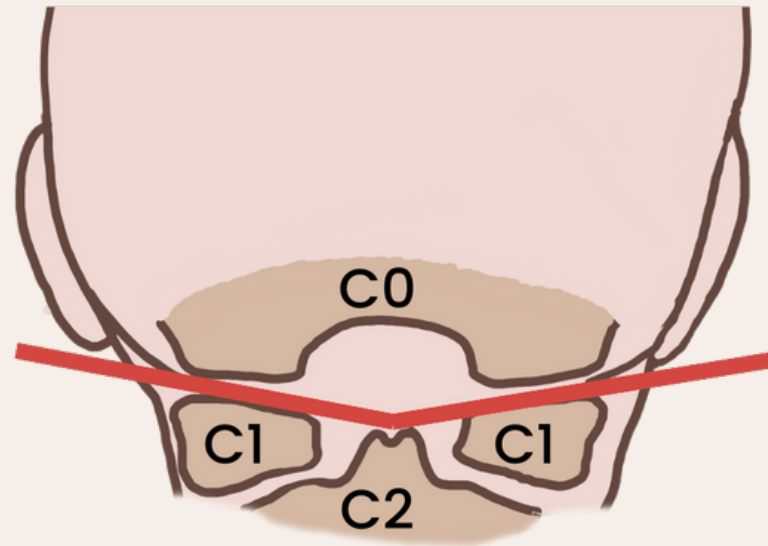


Peristaltische beweging tong
Vacuum houden
Gecoördineerd ademen & slikken

Zuigen
&
Slikken

Occiput- CWK

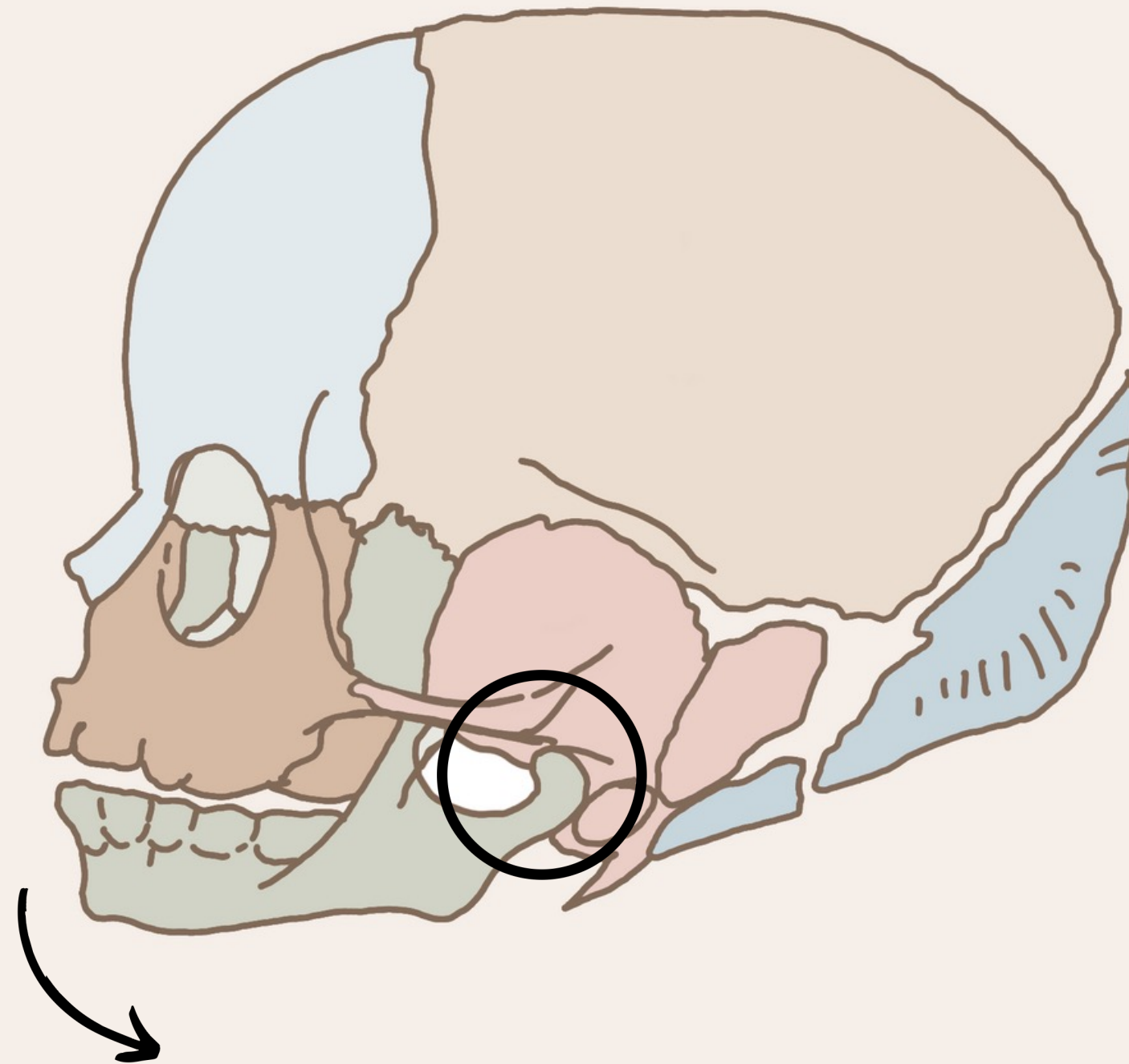
- condylen
- OAA-COMPLEX
- C2-C7



Occiput - CWK

- condylen
- OAA-COMPLEX
- C2-C7

TMG



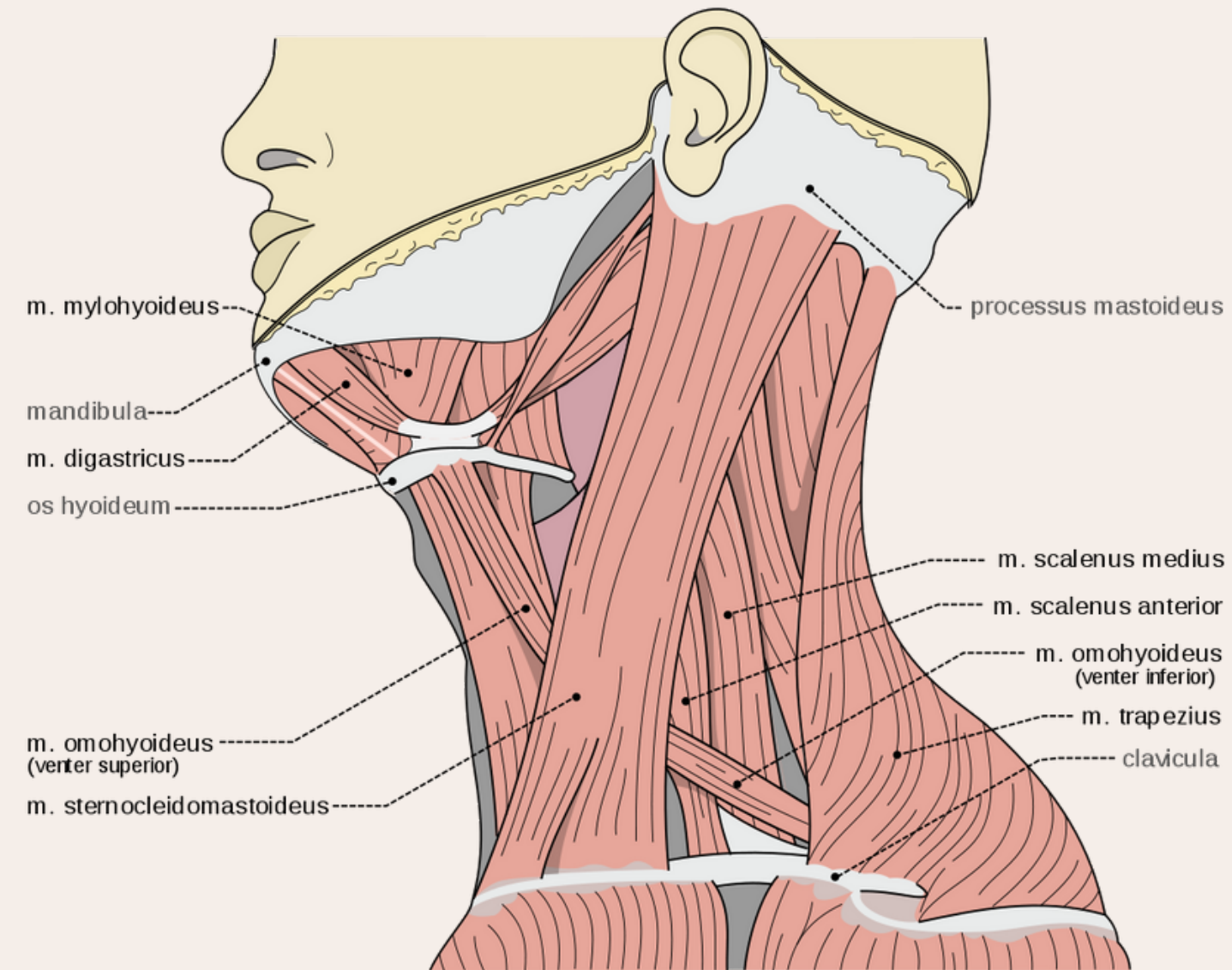
Occiput - CWK

- Condylen
- OAA-COMPLEX
- C2-C7

TMG

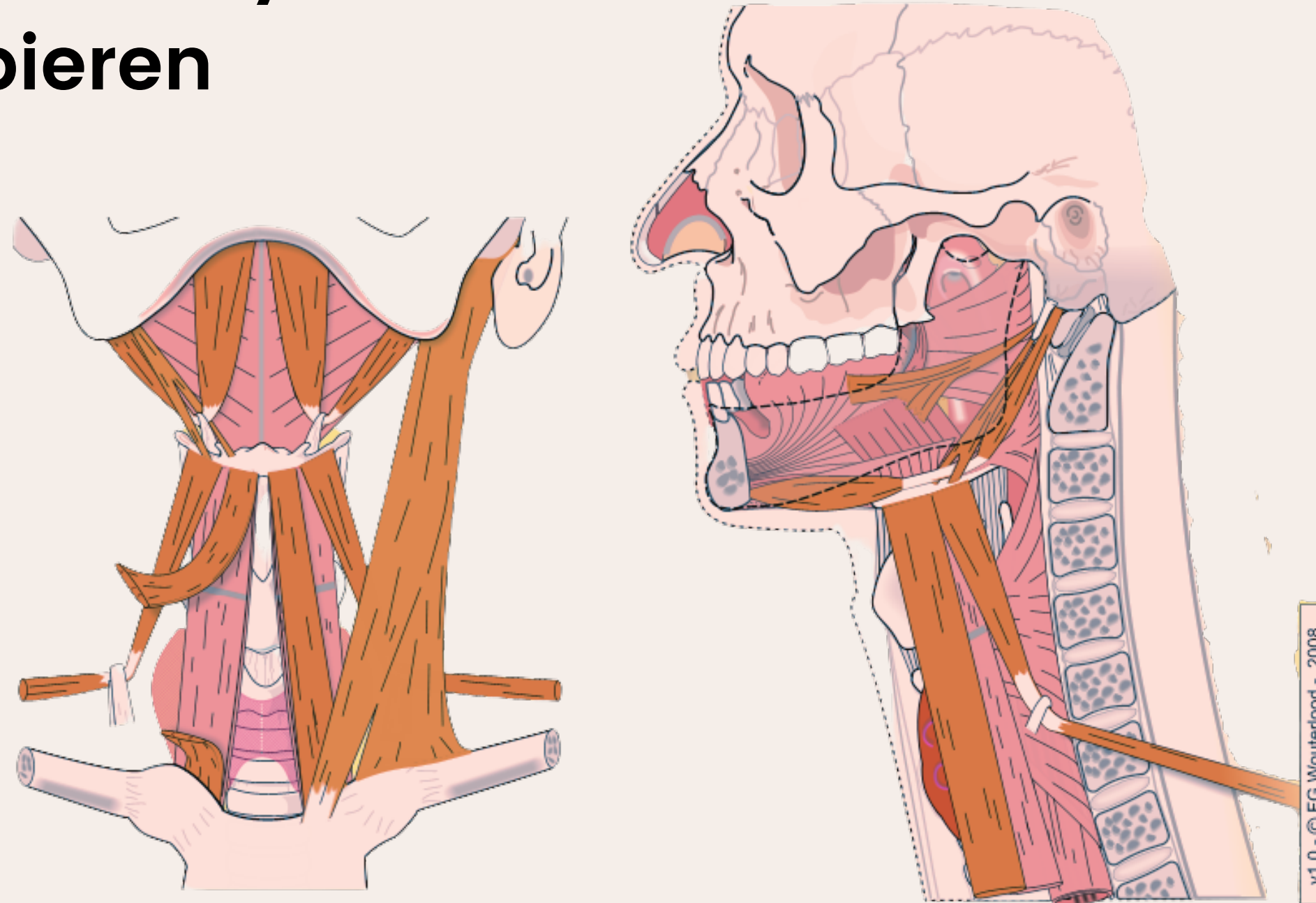
Schoudergordel

- Clavicula
- Sternum
- Scapula



Scheme of muscles of neck (left side, platysma muscle dissected) by Olek Remesz

Supra- en infrahyoidale spieren



Aangepaste afbeelding van www.anatomie-amsterdam.nl

Occiput - CWK

- condylen
- OAA-COMPLEX
- C2-C7

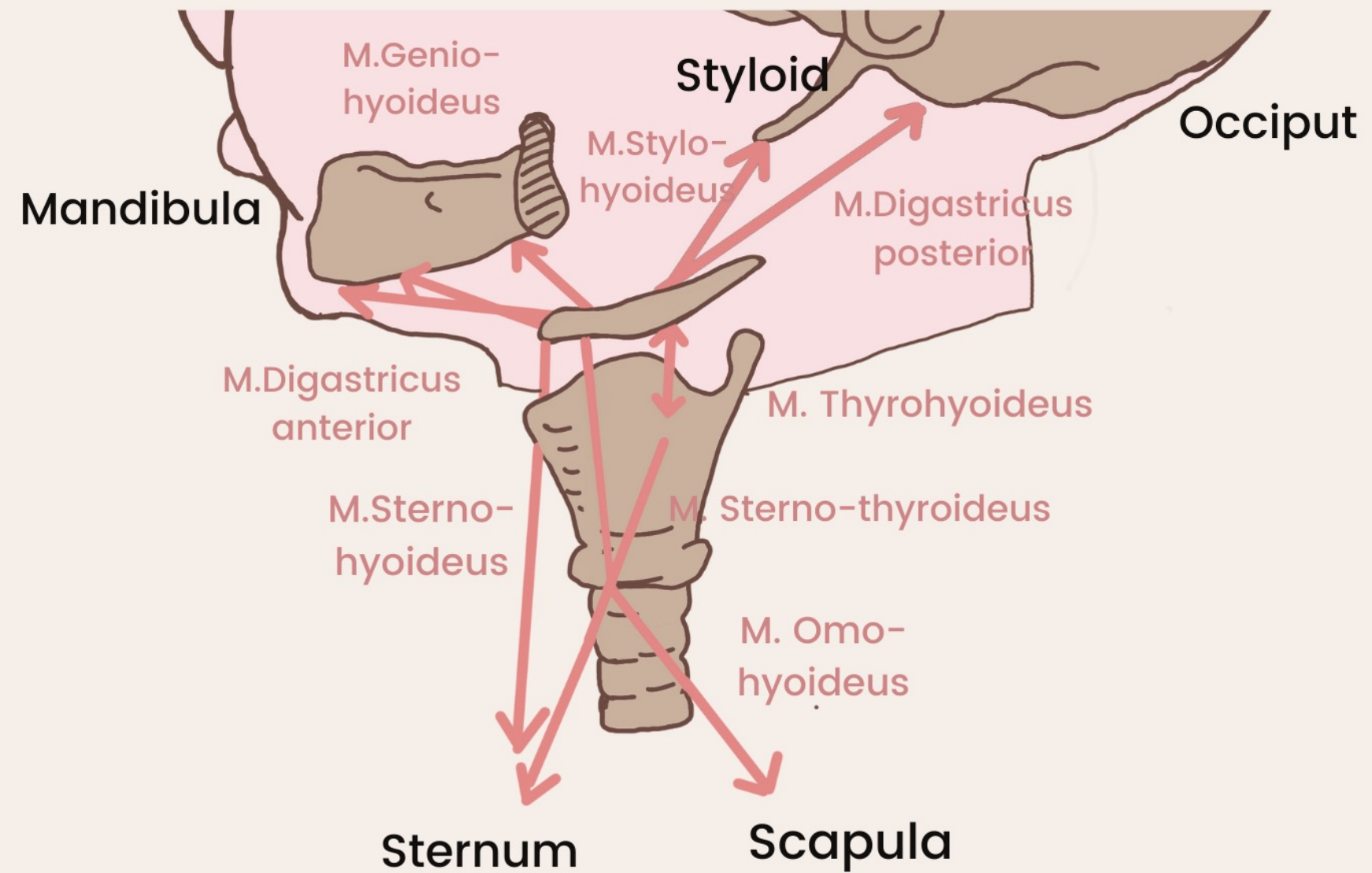
TMG

Schoudergordel

- Clavicula
- Sternum
- Scapula

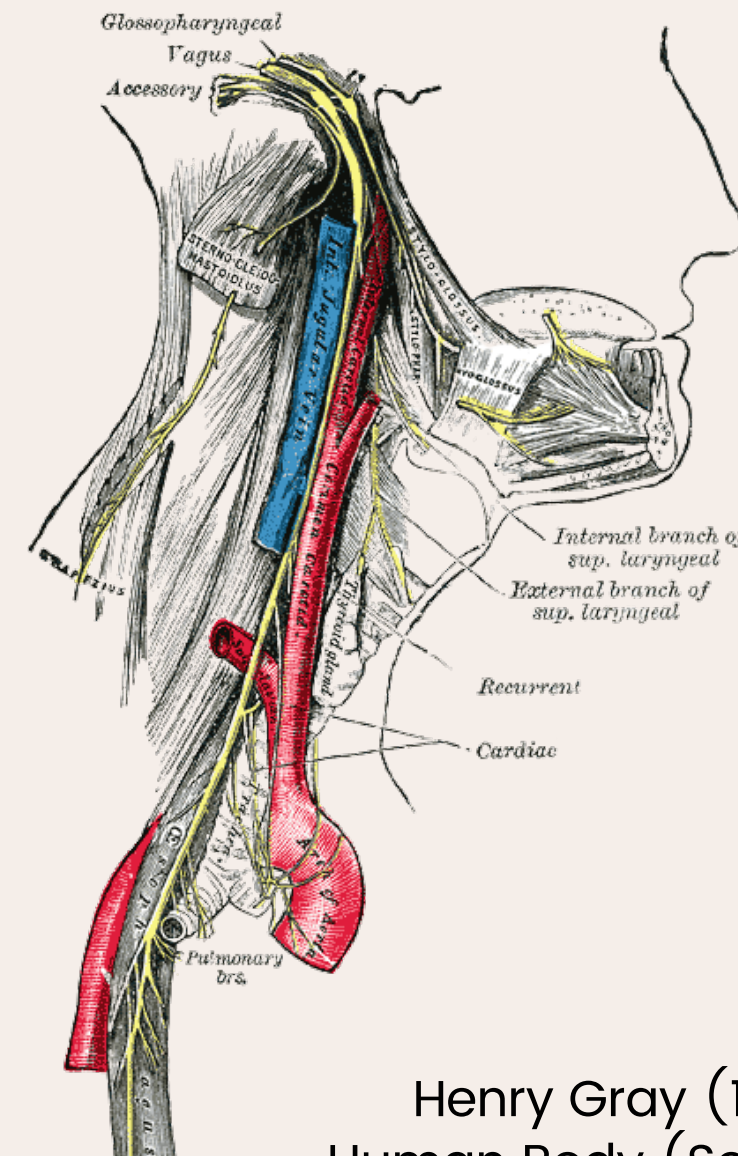
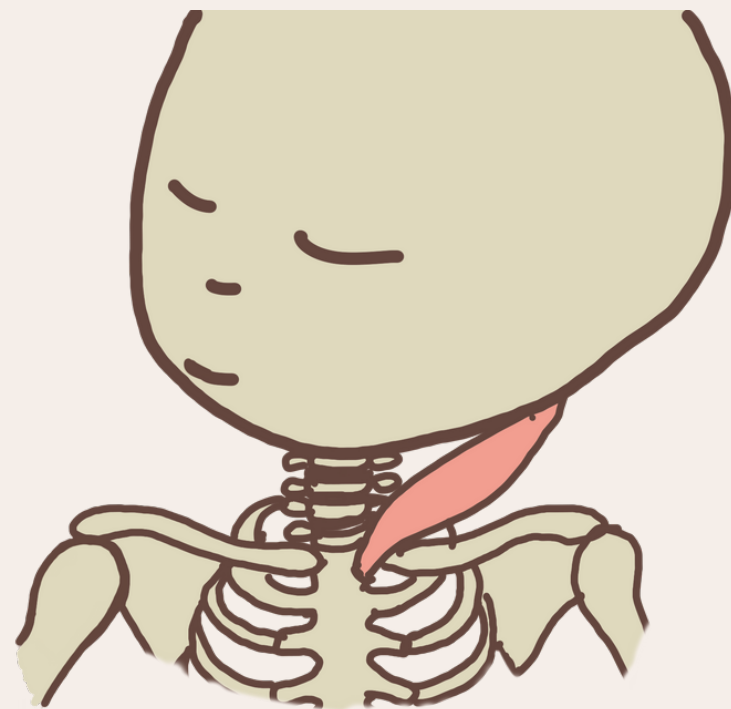
Hyoid

Diafragma



N. XI (N. Accessorius)

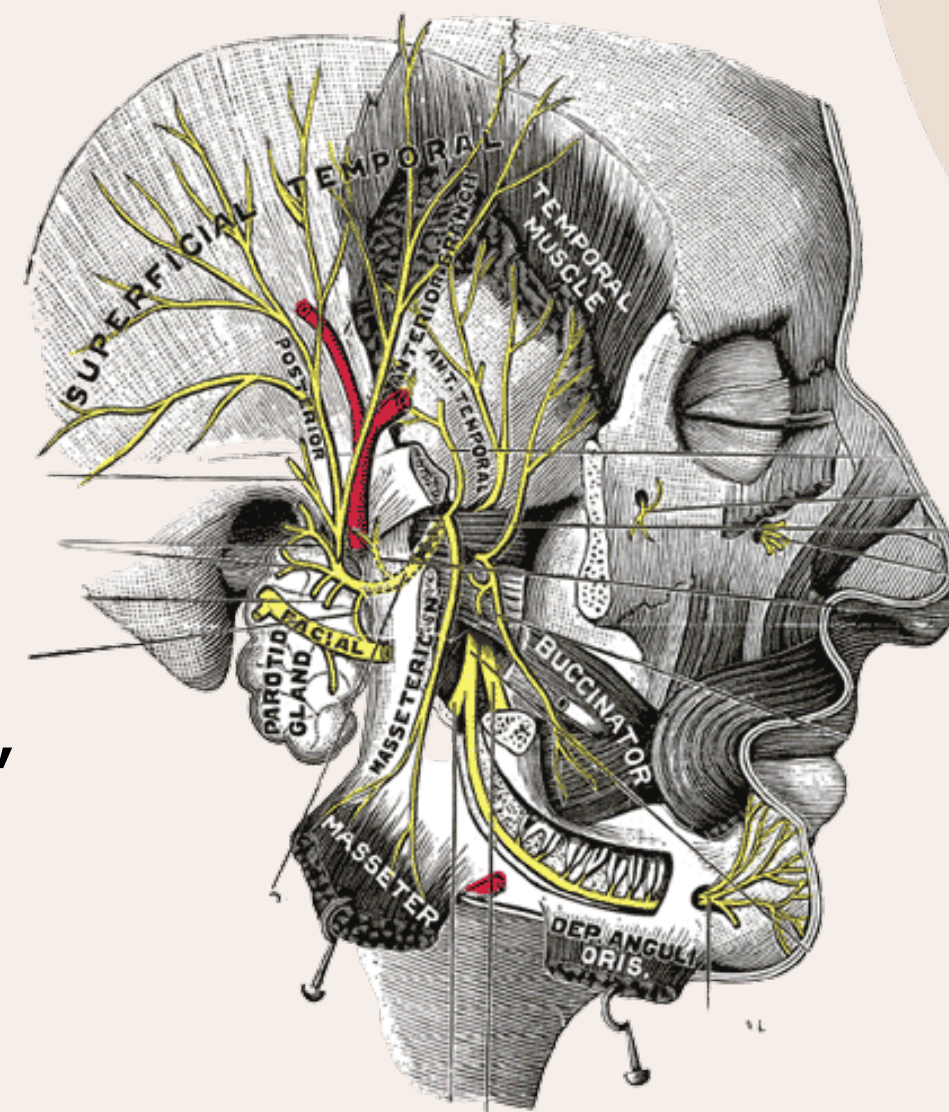
- nekspieren/ M. S.C.M, M. Trapezius



Henry Gray (1918) Anatomy of the Human Body (See "Boek" section below)
Bartleby.com: Gray's Anatomy, Plaat 793

N. V (Trigeminus)

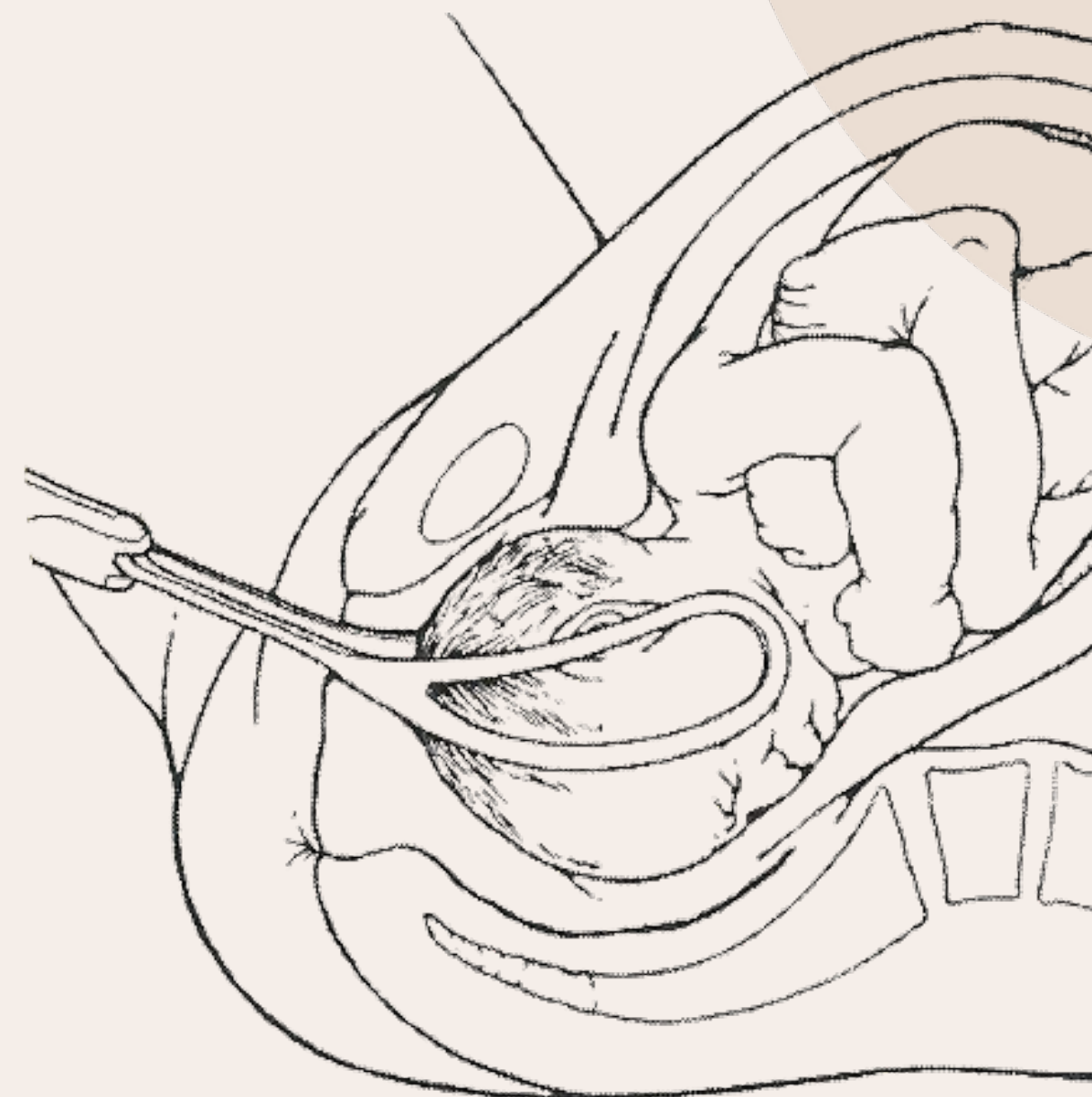
- V2: N. Maxillaris
 - sens: bovenkaak, bovenlip, zacht gehemelte, neus, kaakholte
- V3: N. Mandibularis
 - sens: onderkaak, onderlip, tong, meat.ac. int, hersenvliezen
 - mot: kauwspieren



Henry Vandyke Carter- Henry Gray (1918) Anatomy of the Human Body
(See "Boek" section below) Bartleby.com: Gray's Anatomy, Plaat 781

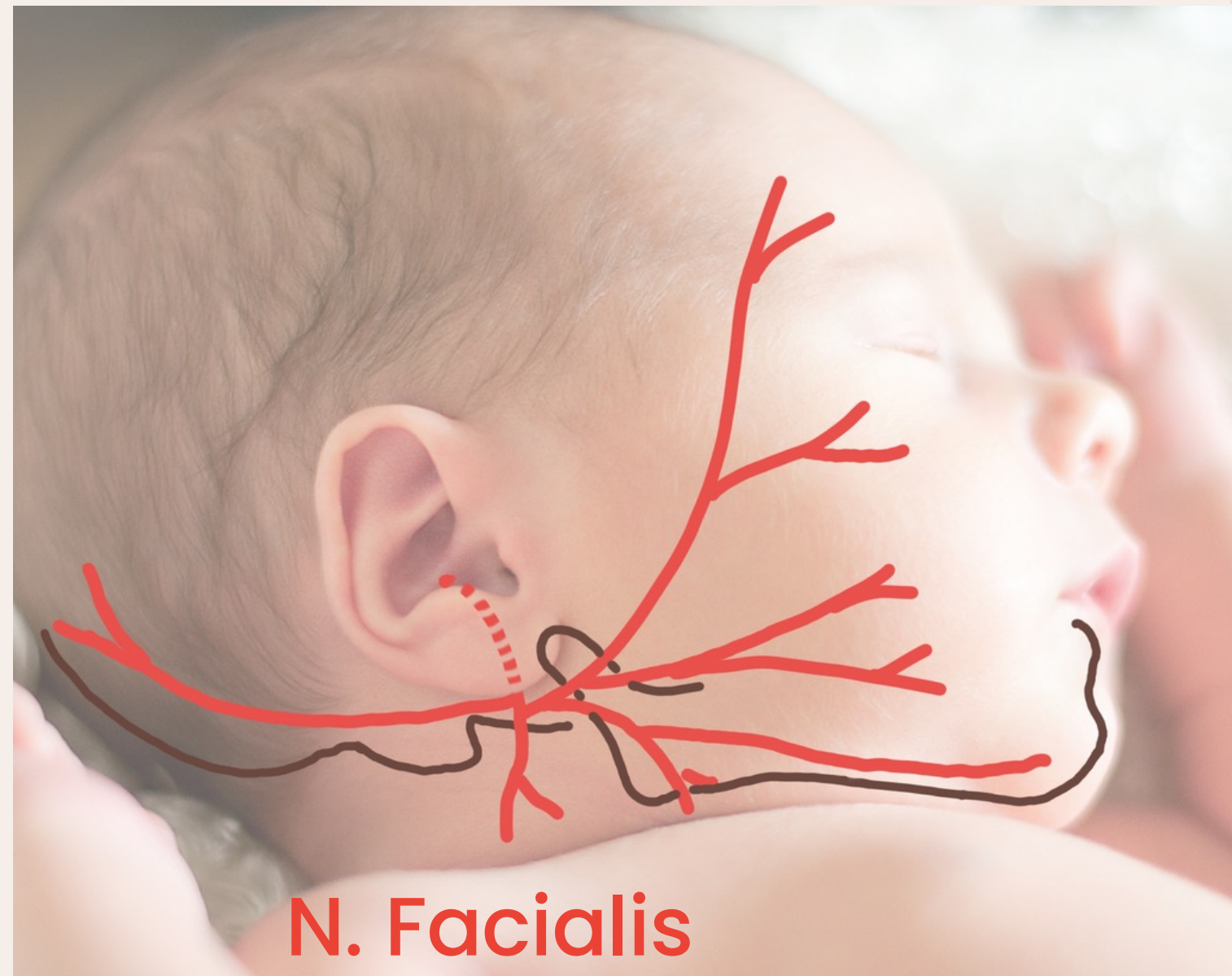
N. V (Trigeminus)

- **V2: N. Maxillaris**
 - sens: bovenkaak, bovenlip, zacht gehemelte, neus, kaakholte
- **V3: N. Mandibularis**
 - sens: onderkaak, onderlip, tong, meat.ac. int, hersenvliezen
 - mot: kauwspieren



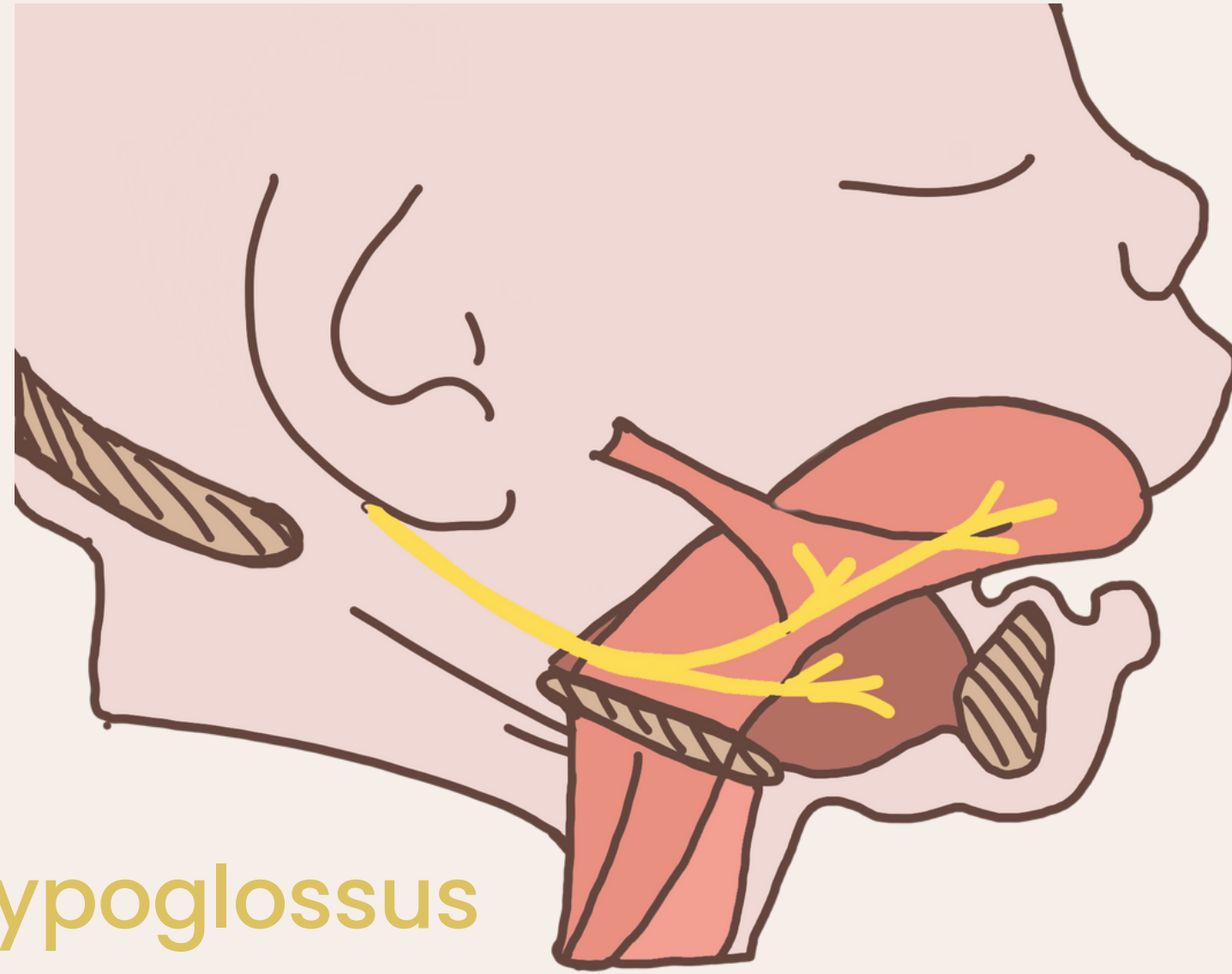
N. VII (Facialis)

- sens. smaak
- mot: gelaatsspieren



N. XII (Hypoglossus)

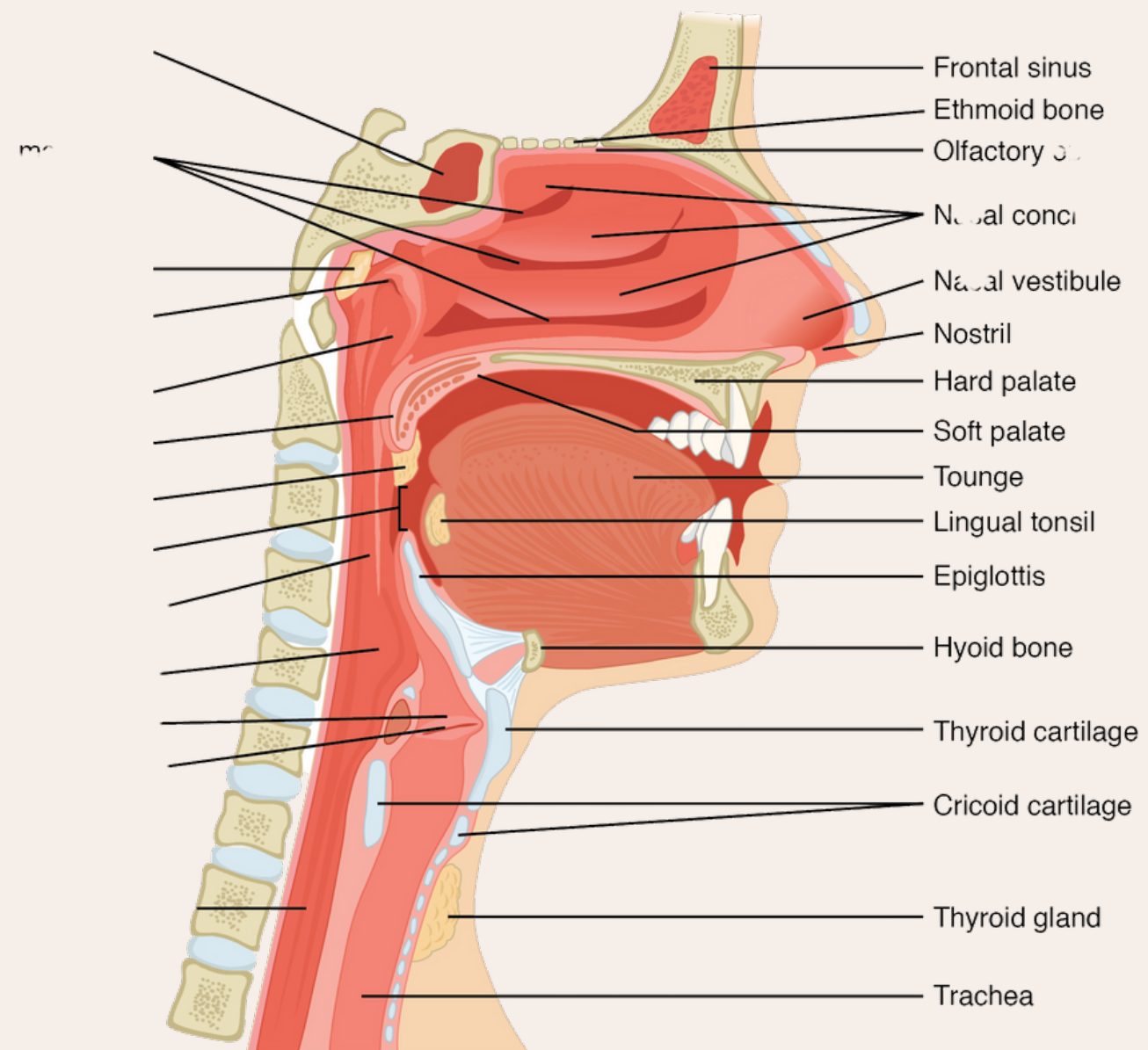
- tongspieren



N. Hypoglossus

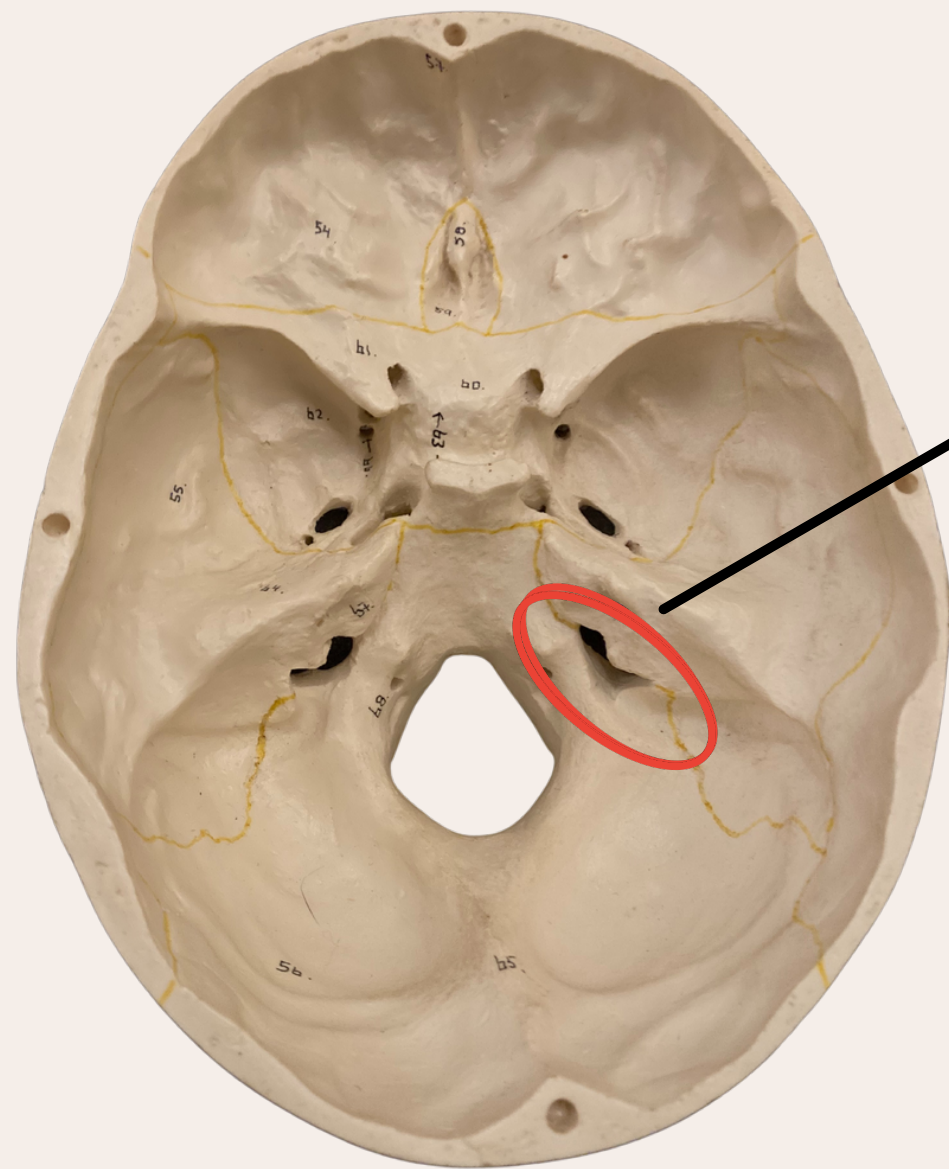
Tong-
spieren

N. N IX (Glossopharyngeus) en X (Vagus)

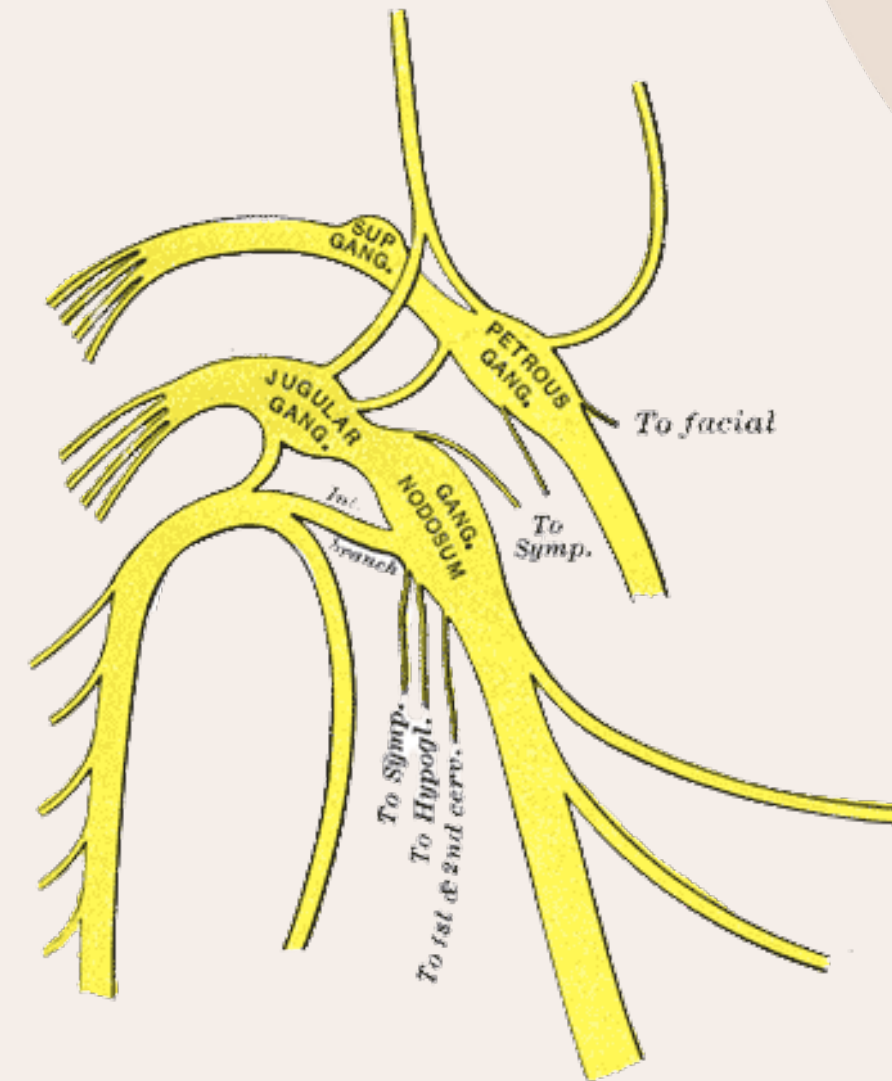


Source Anatomy & Physiology, Connexions Web site.
<http://cnx.org/content/col11496/1.6/>, Jun 19, 2013.

N. N IX (Glossopharyngeus) en X (Vagus)

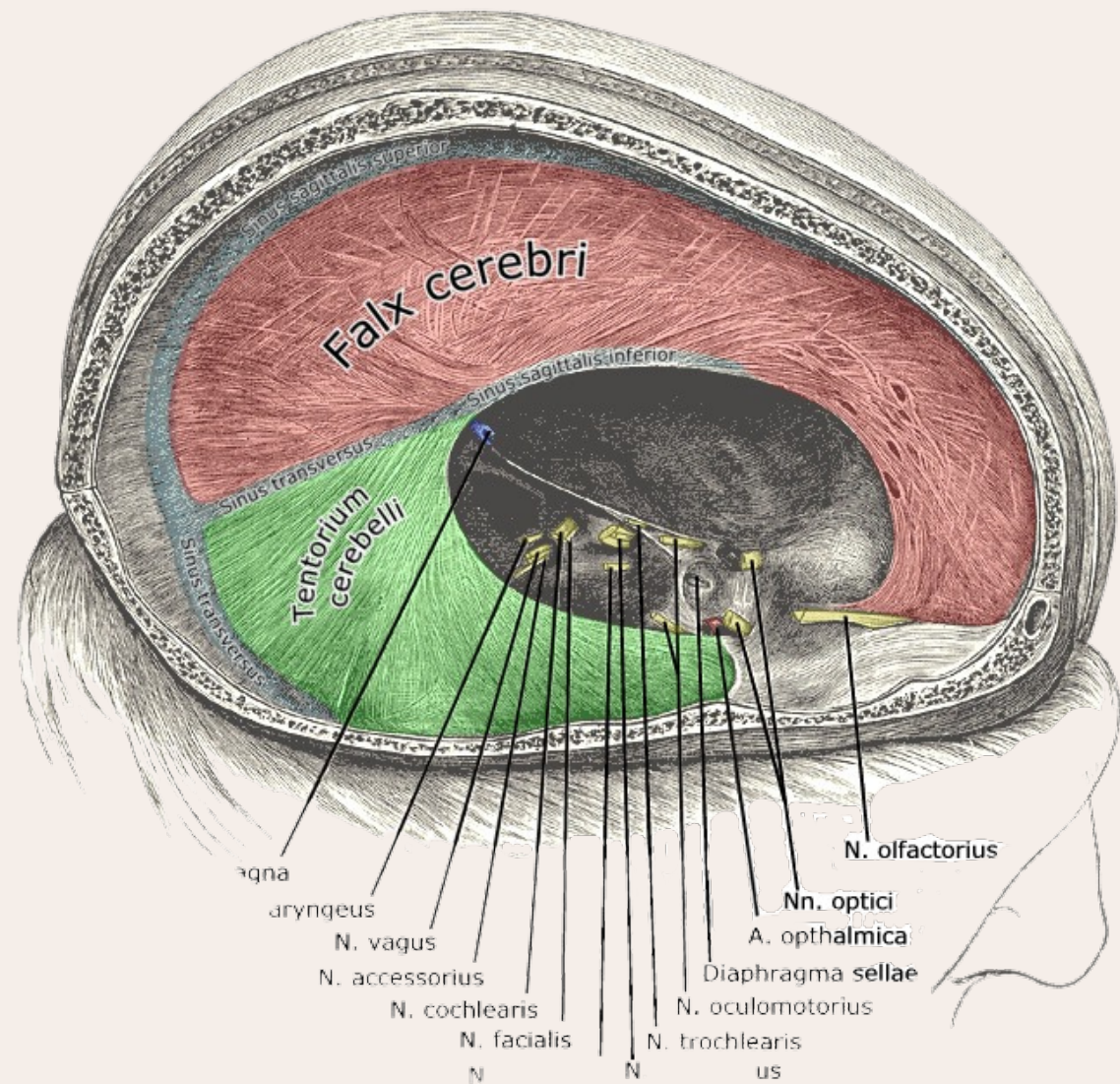


- N. X (Vagus)
- N. IX (Glossopharyngeus)
- N. XI (Accessorius)



Henry Vandyke Carter - Henry Gray (1918)
Anatomy of the Human Body (See "Boek" section
below) Bartleby.com: Gray's Anatomy, Plaat 791

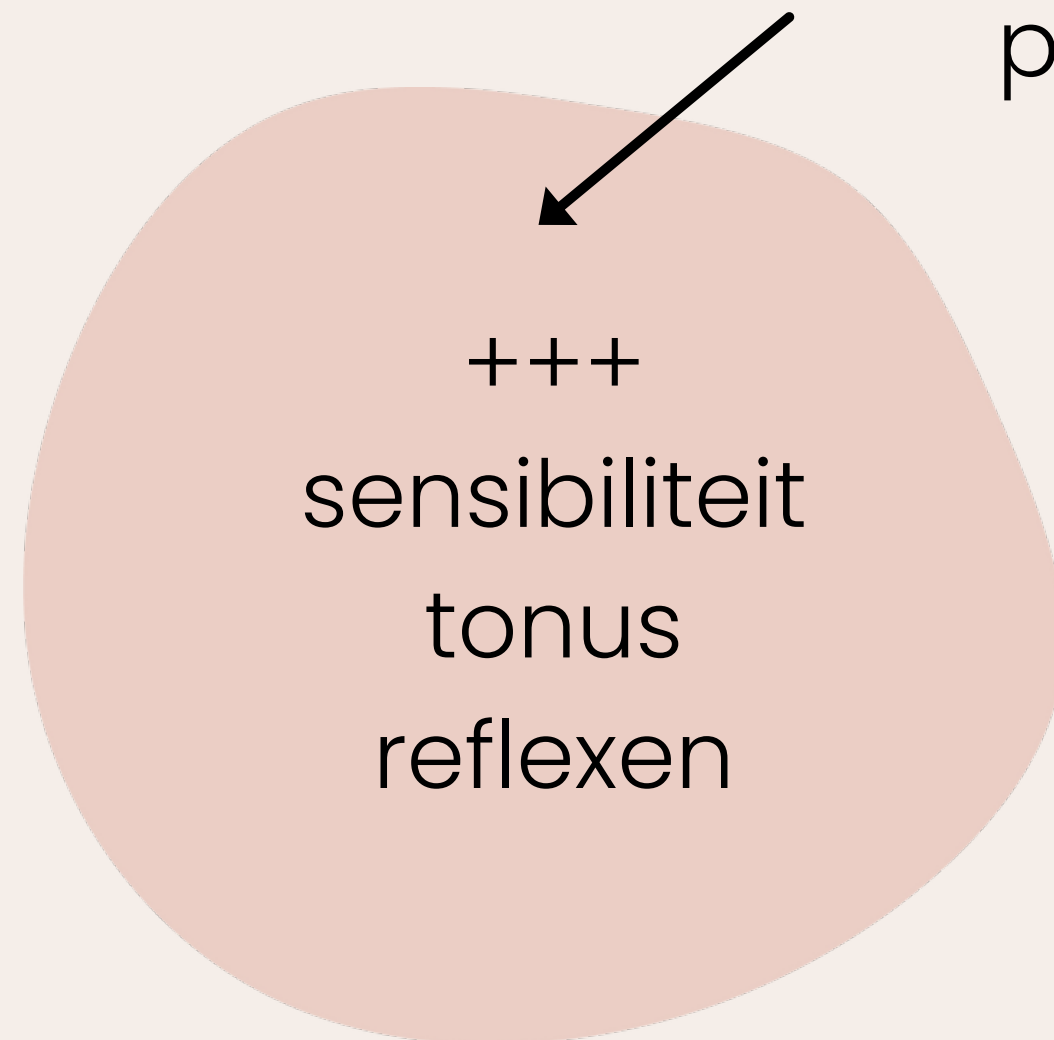
Hersen- vliezen



Blumenfeld H, Neuroanatomy through Clinical Cases, 2e editie. Sinauer Associates, Sunderland, MA, VS (2010). ISBN 978-0-87893-613-7.

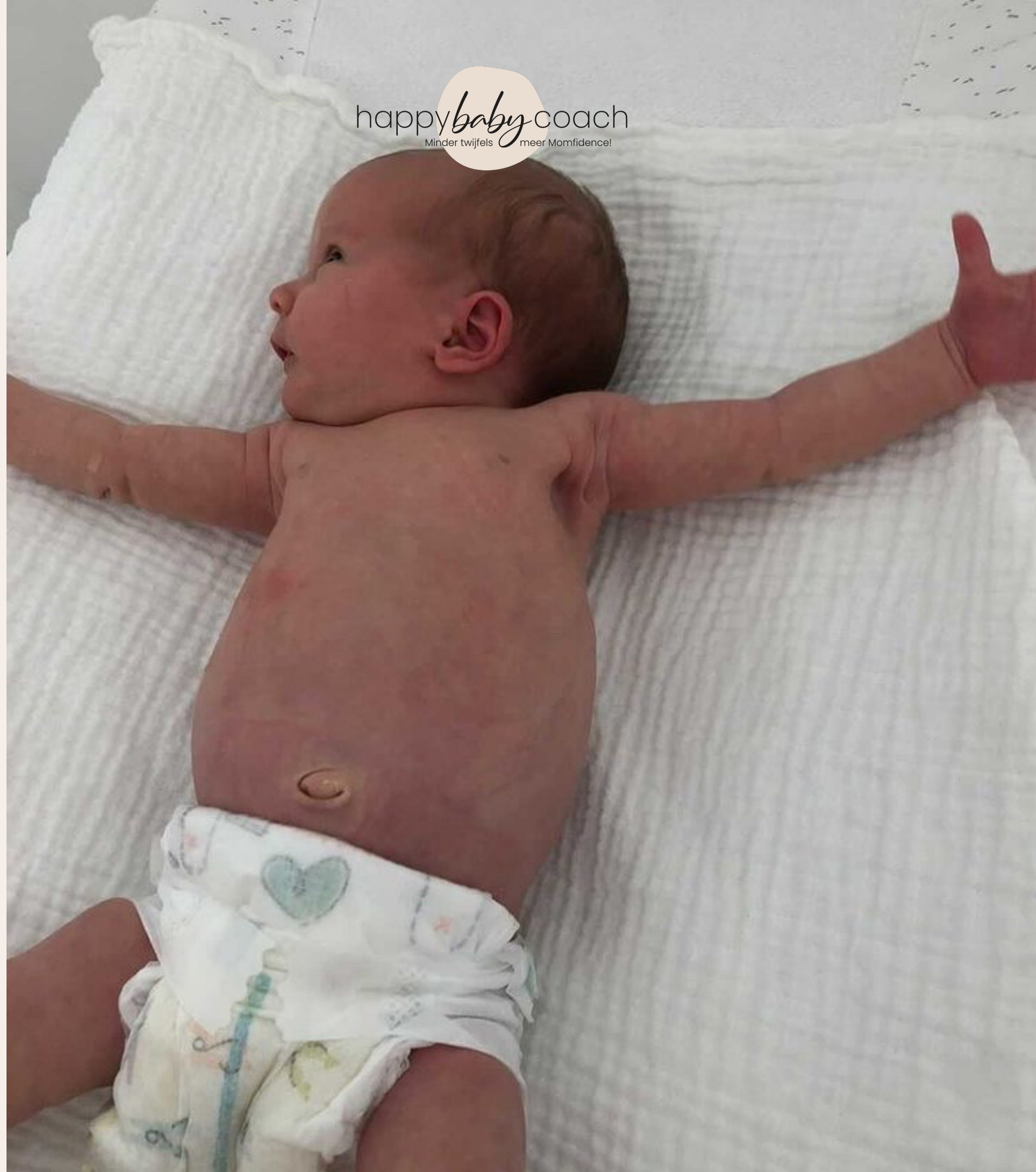Pijn + bewegingsverlies (in cranium / CWK)

hersenstam in verhoogde
paraatheid

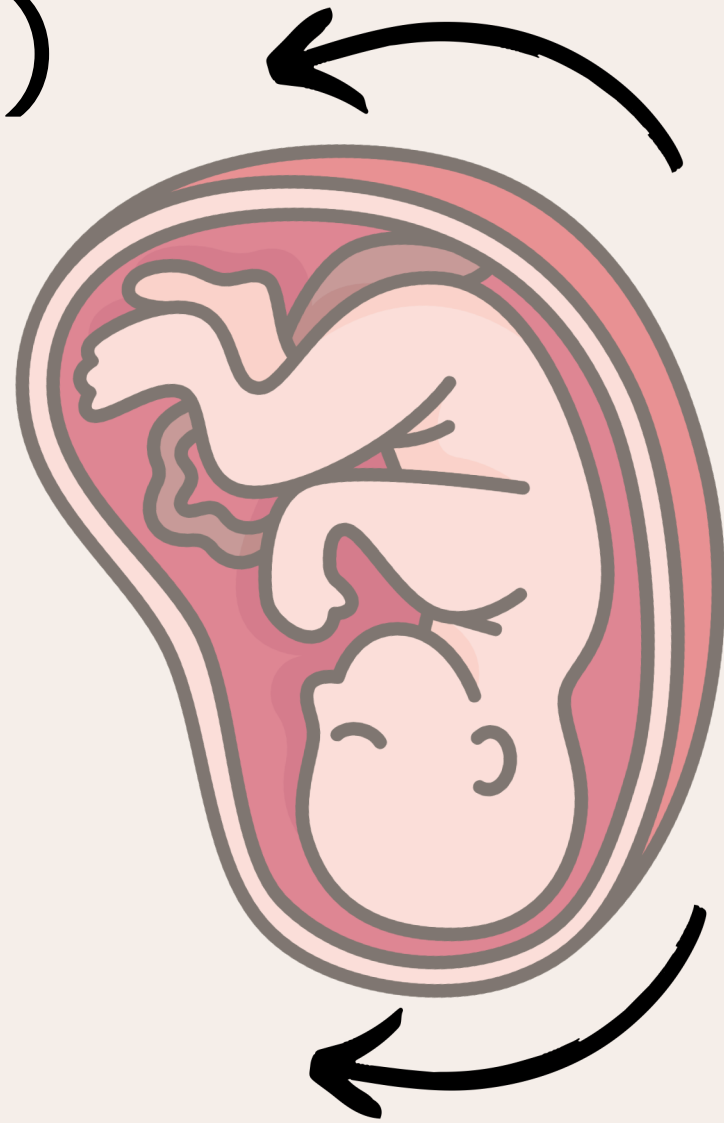


'Neurofysiologisch verklaringmodel van
osteopathie bij pasgeborenen' René Zweedijk

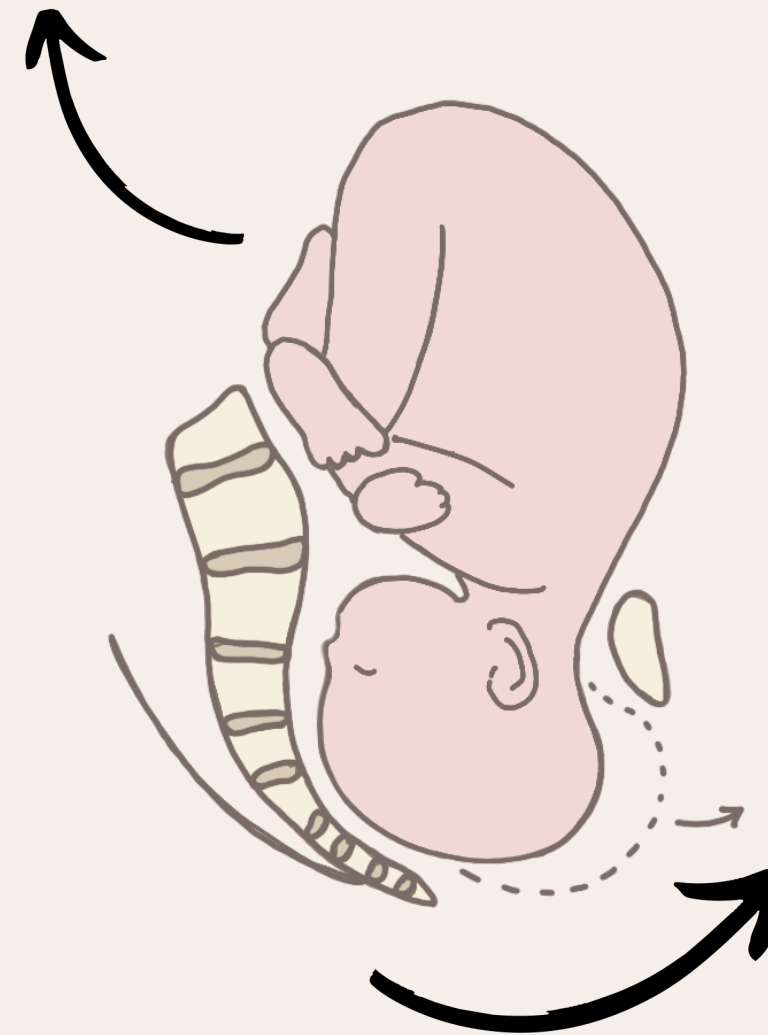
Moro-reflex



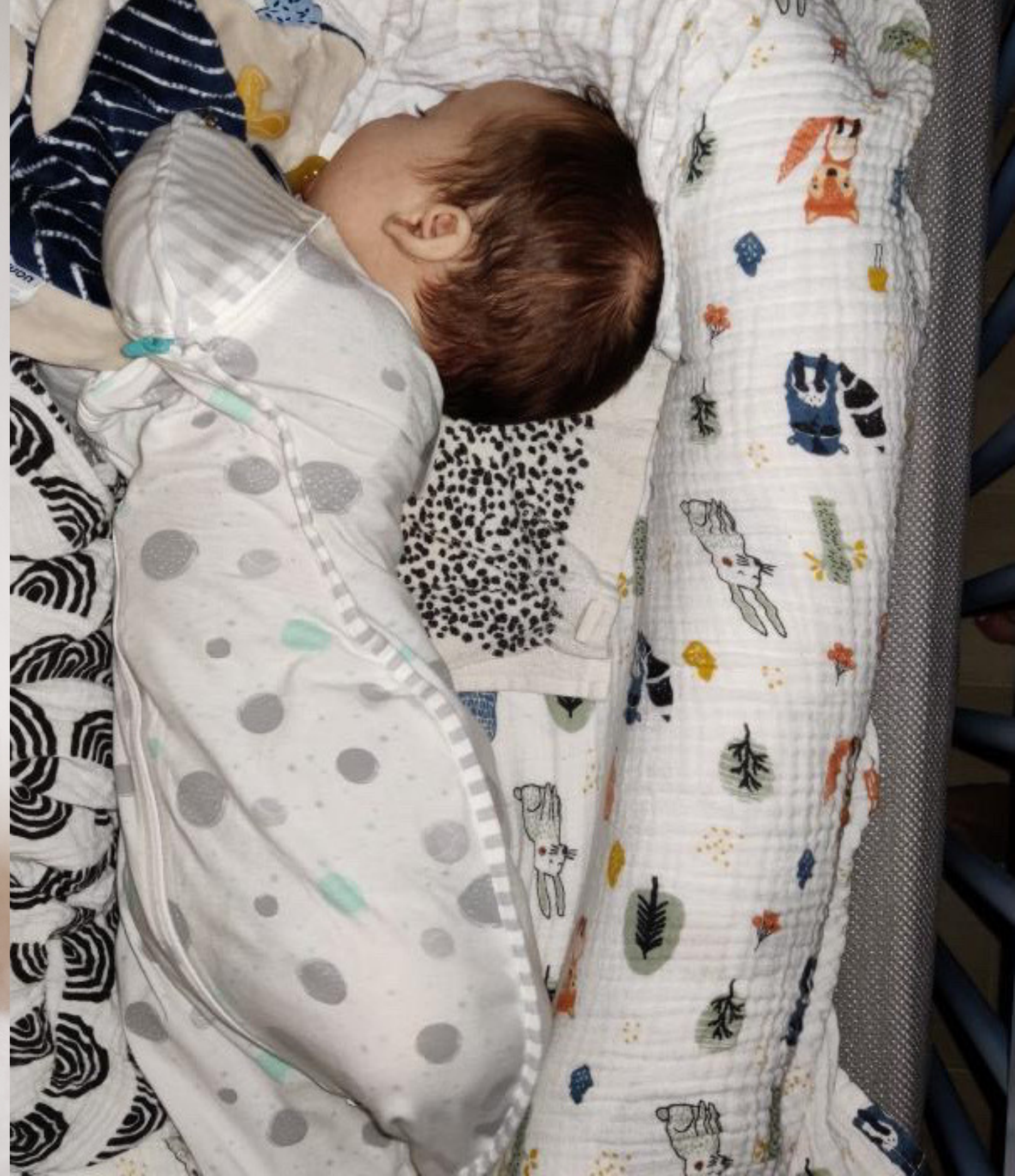Tonische Labyrinthreflex (TLR)



Voorwaartse



Achterwaartse



happy baby coach
Minder twijfels meer Momfidence!



**Asymmetrische
Tonische
Nekreflex
(ATNR)**

happy baby coach
Minder twijfels meer Momfidencel

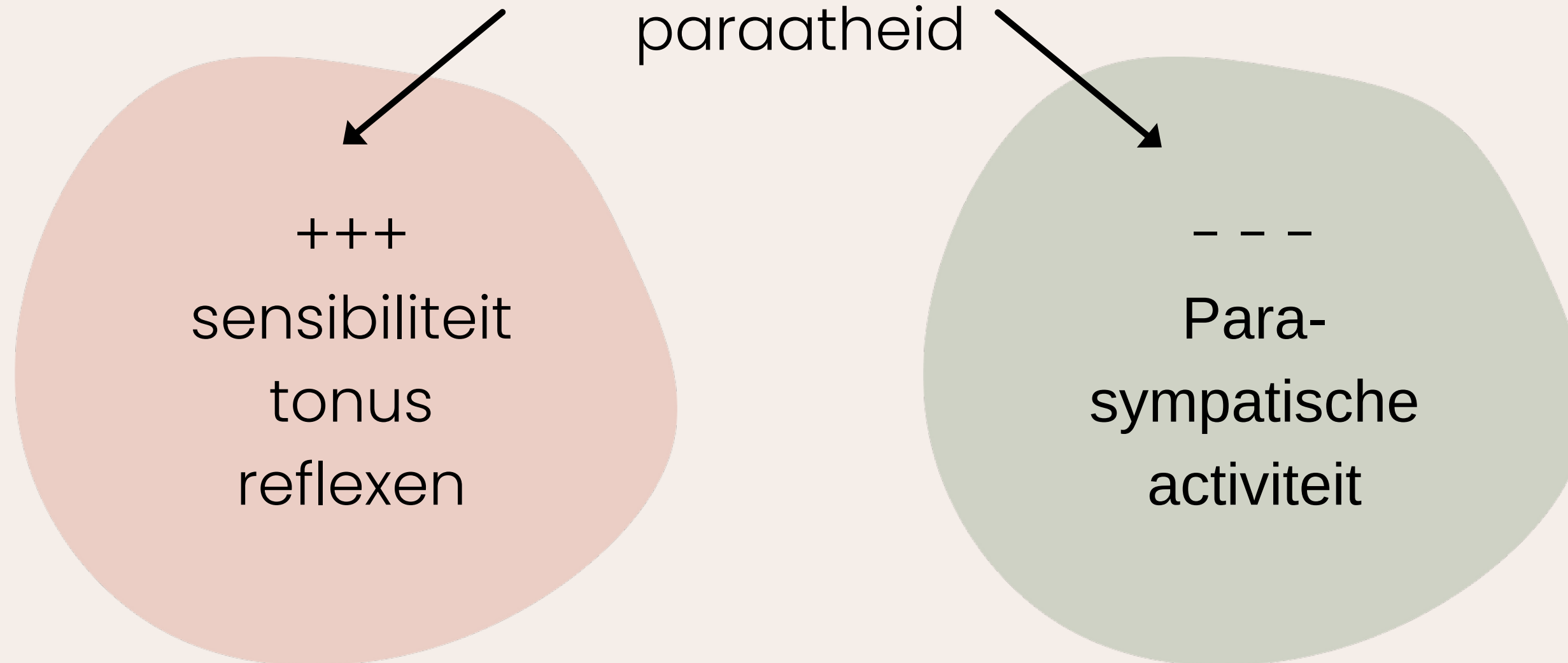


Zoek-, zuigreflex



Pijn + bewegingsverlies (in cranium / CWK)

hersenstam in verhoogde
paraatheid



'Neurofysiologisch verklaringmodel van
osteopathie bij pasgeborenen' René Zweedijk

Wanneer kan osteopathie
zinnvol zijn?

Wanneer
osteopathie?

Anamnese

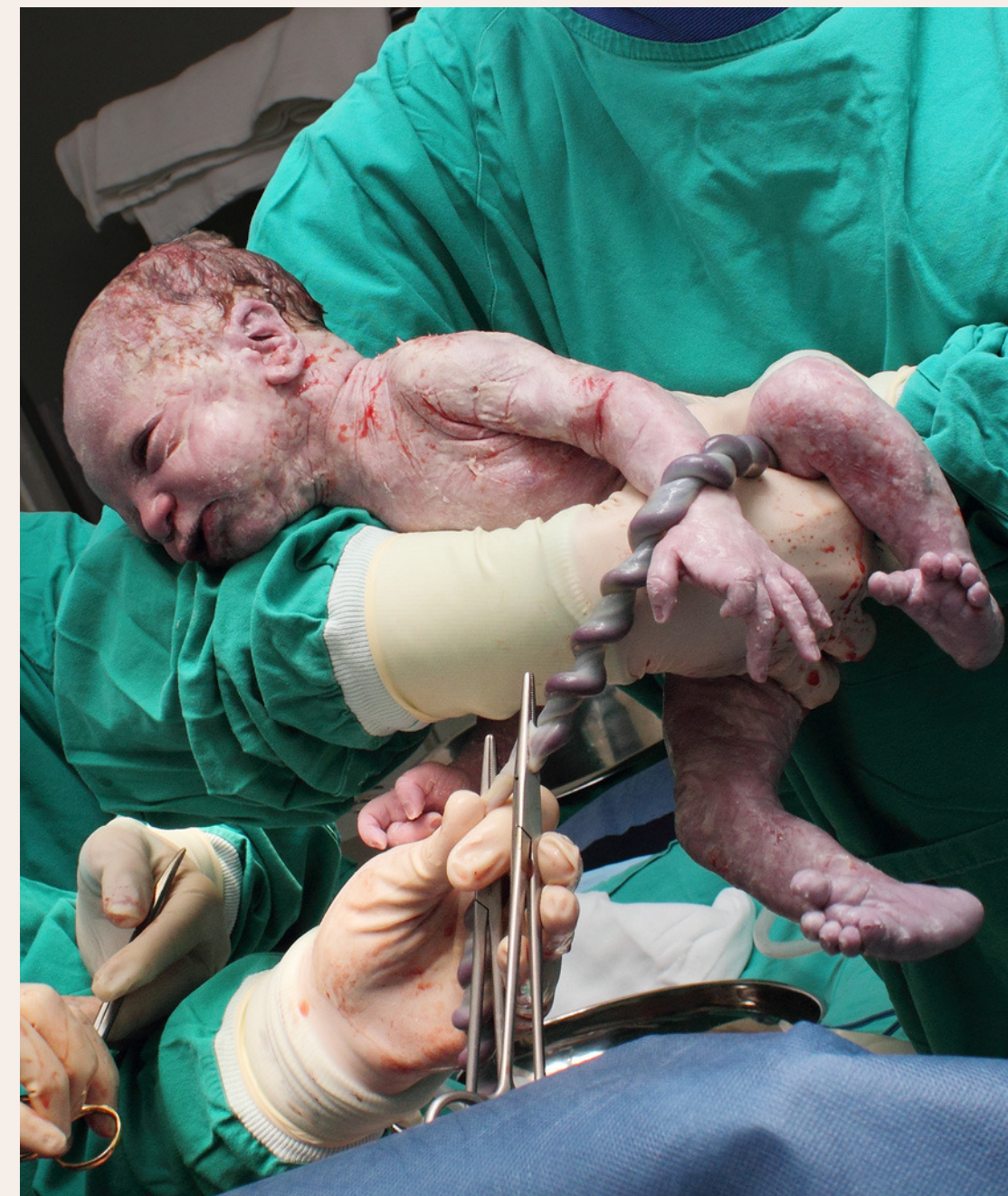Risicofactoren tot verstoring lichaamsbalans

- Geboorte: grotere krachtsinwerkingen?
 - weeën stilgevallen, inleiding/augmentatie
 - klem gezet met hoofdje of schouders, fundusdruk, ventouse, verlostang, (spoed)keizersnede
 - Liggingafwijking
 - Prematuriteit
 - pijnprikkels

Wanneer
osteopathie?

Meteten na de geboorte

- o eerste adem moeilijk
- o bruuske, snelle afnaveling



Wanneer
osteopathie?

OBSERVATIE/ONDERZOEK

- Moeite om hoofdje achterwaarts te kantelen
- Asymmetrie in vorm/houding/beweging?
(Hoofdje/aangezicht/romp/ledematen)
- Moeite met aankleden, bvb 1 arm niet goed door truitje? Trui over hoofdje lastig?
- Mondje dat niet breed kan openen (kleine aanhap)
- Beperkte beweeglijkheid tong hoewel geen restrictieve tongriem
- Primaire reflexen overactief




happy baby coach
Minder twijfels meer Momfidence!

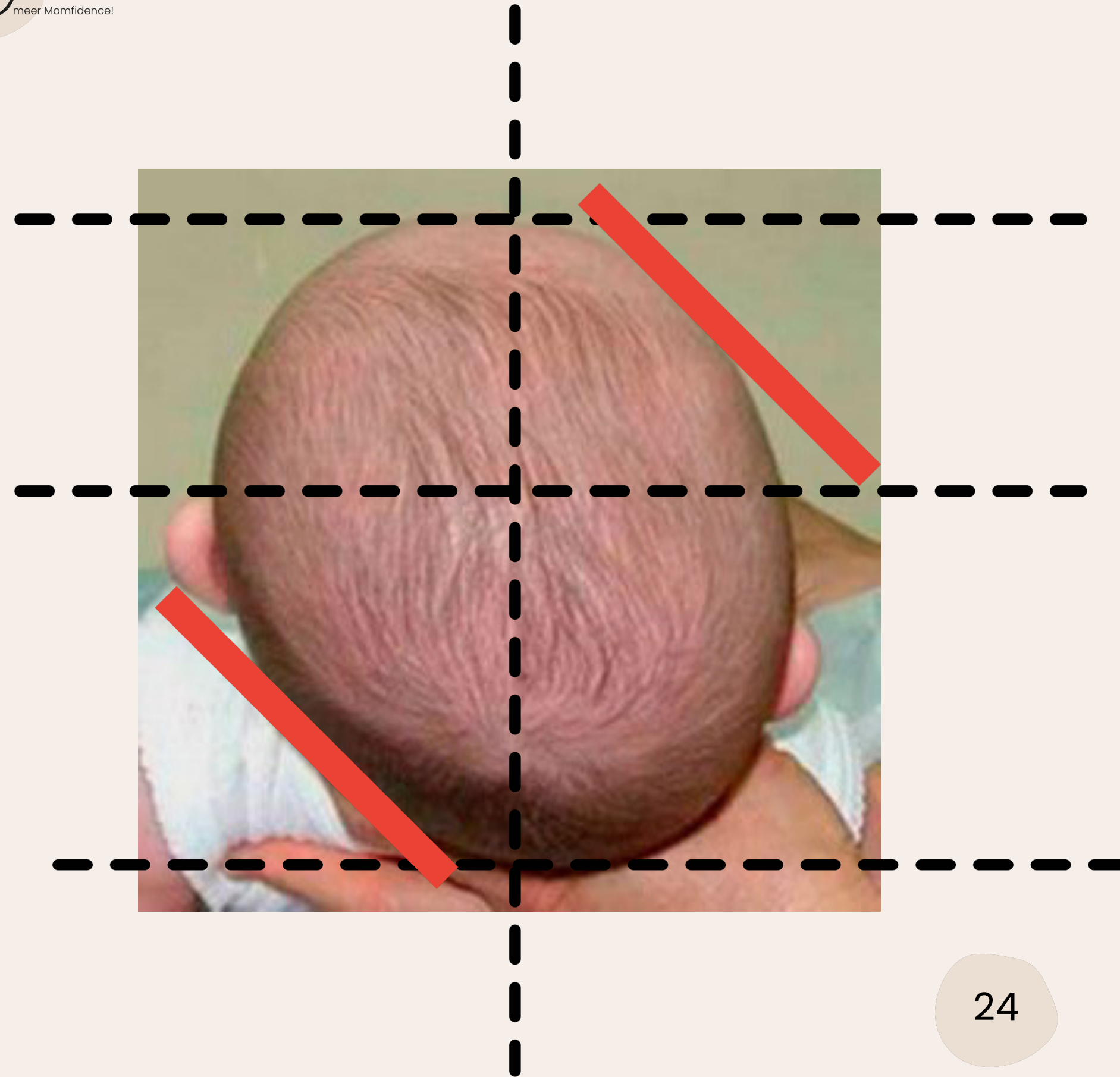
Geen
vlotte
kanteling


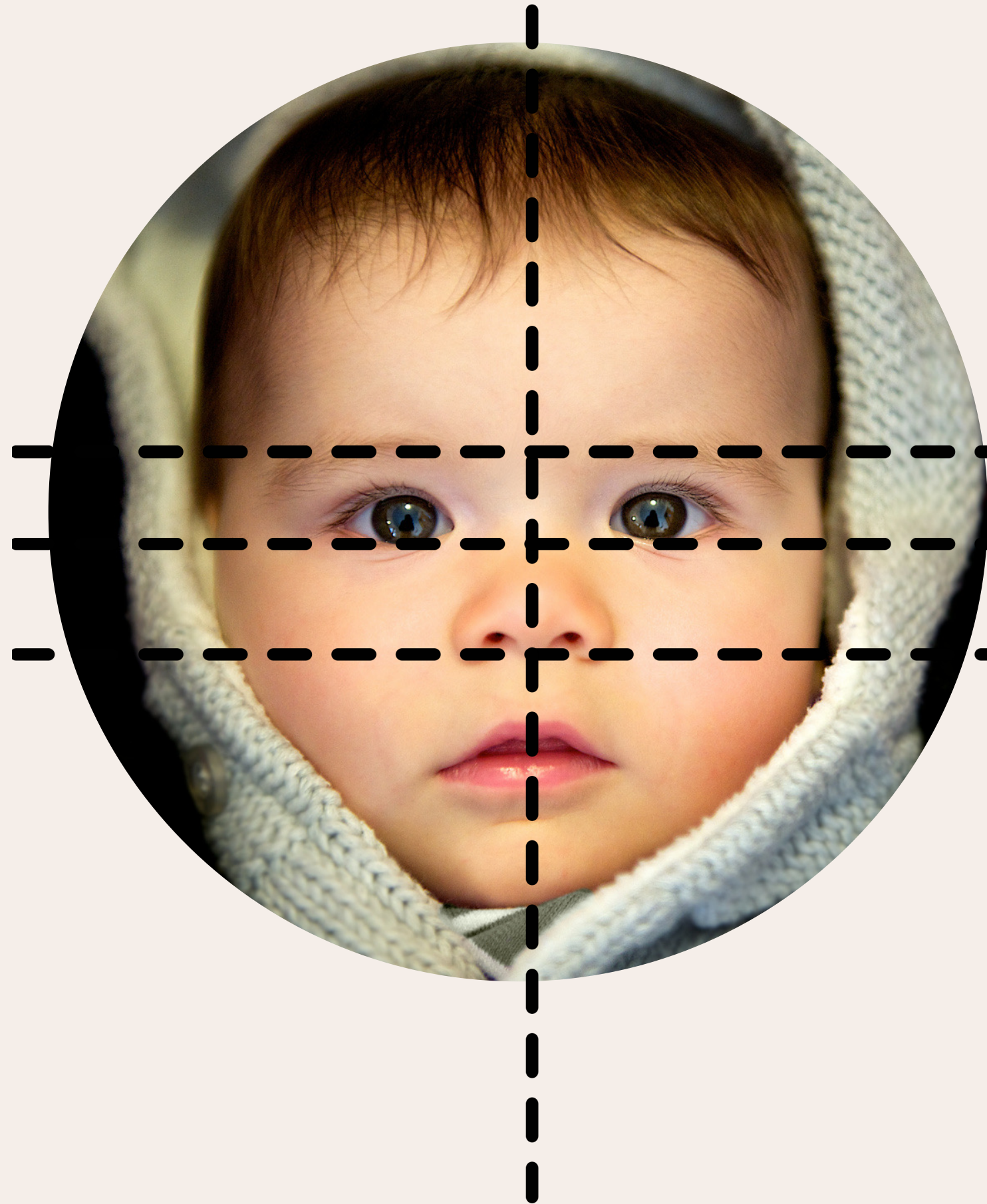
Wel vlotte
kanteling





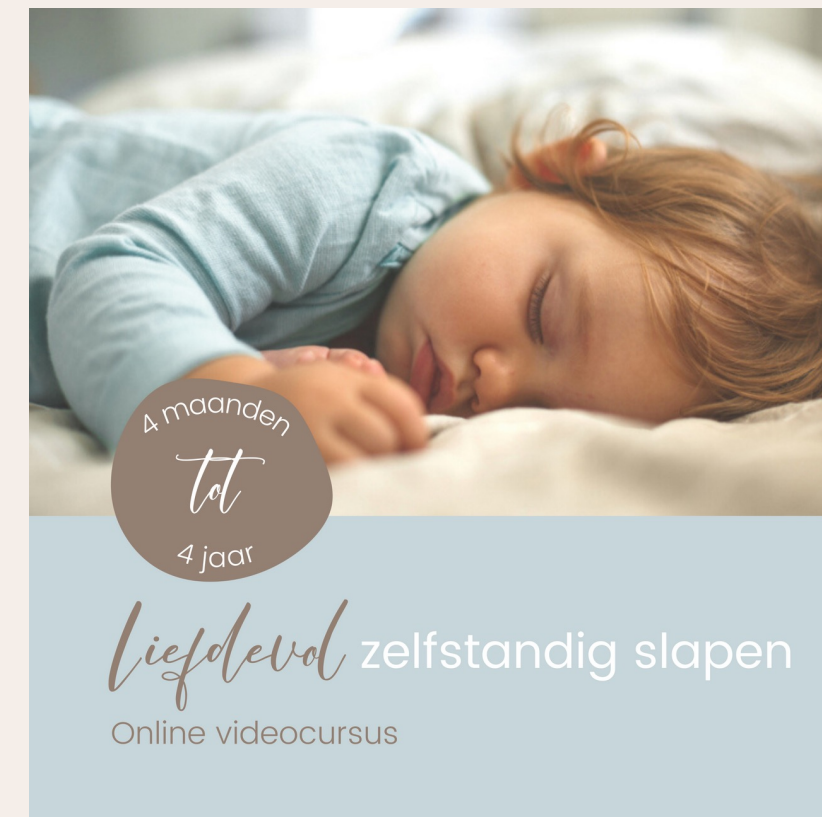
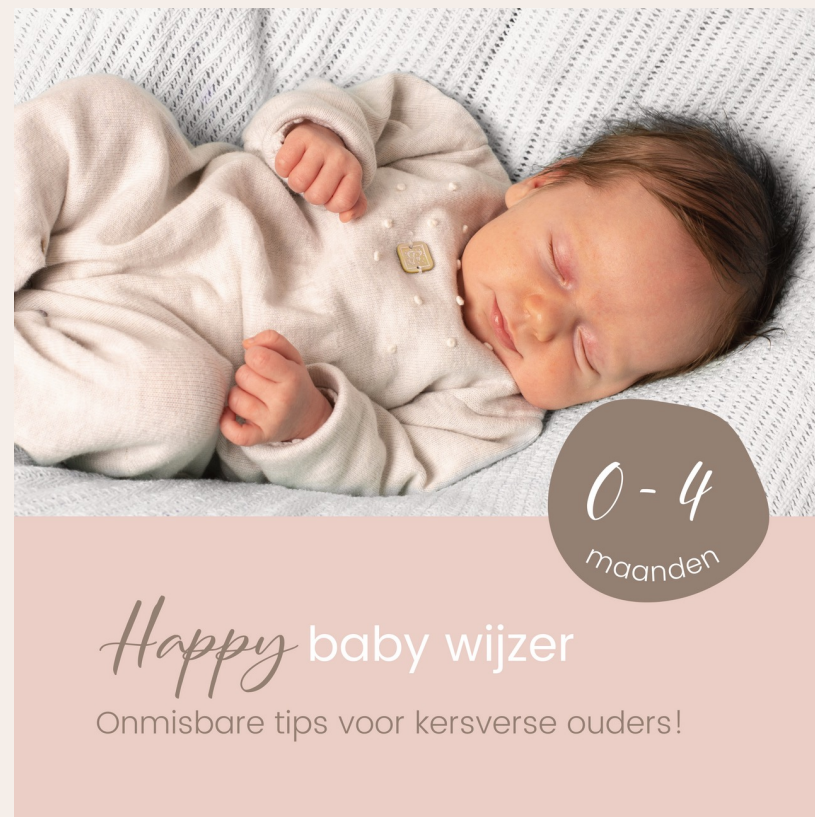




happy baby coach

Minder twijfels meer Momfidence!



www.happybabycoach.com
info@happybabycoach.com

Boeken en artikels

- Carreiro 2009: An osteopathic approach to children: Chapter 14.
- Genna 2013: Supporting sucking skills in breastfeeding infants: chapter 10.
- Herzhaft-Le Roy J, Xhignesse M, Gaboury I. Efficacy of an Osteopathic Treatment Coupled With Lactation Consultations for Infants' Biomechanical Sucking Difficulties: A Randomized Controlled Trial. *Journal of Human Lactation*. 2017;33(1):165-172. doi:10.1177/0890334416679620
- Righard M/ en M. O. Alade. (1990). "Effect of delivery room routines on succes of first breast-feed", *The Lancet*, vol 336, 1105-1107
- Fraval M 1998 A pilot study: Osteopathic treatment of infants with a sucking dysfunction *Journal of the American Academy of Osteopathy*
http://www.osteopathicresearch.com/index.php?option=com_jresearch&view=publication&task=show&id=12345&lang=en
- Herzhaft-Le Roy J., MD, DO, IBCLC, Xhignesse M., MD, MSc, Gaboury I., PhD. (dec. 2016). "Efficacy of an Osteopathic Treatment Coupled With Lactation Consultations for Infants' Biomechanical Sucking Difficulties: a Randomized Controlled Trial". *Journal of Human Lactation* Volume: 33 issue: 1, page(s): 165-172



- Khraim N 1999 Osteopathic treatment of an infant with a failure to suck Australian Journal of Osteopathy 10:1 15–16
- Lund GC, Edwards G, Medlin B, Keller D, Beck B, Carreiro JE. 2011 Osteopathic manipulative treatment for the treatment of hospitalized premature infants with
- Magoun 1976. osteopathy in the cranial field. 3rd ed. Journal printing CO. Kirksville MO.
- Maxwell M.P.R. Fraval DO, M. Osteo. Sc. (Paed.) (1998). "A pilot study: Osteopathic treatment of infants with a sucking dysfunction" Osteopathic Medical Digital Repository., p. 26–33.
- Smith L, Kroeger M. impact of birthing practices on breastfeeding. 2nd ed. sudbury: Jones and barlett's publishers; 2010.



Links

http://samples.jbpub.com/9781284093919/9781284093919_CH03_GennaSample.pdf

<https://journals.sagepub.com/doi/10.1177/0890334416679620>

<http://www.ncbi.nlm.nih.gov/pubmed/21258016>

http://www.anatomie-amsterdam.nl/sub_sites/slikken_website/html_pages/supra_infracoroidaal_mm_nolabel.htm